



DRY AGE-RELATED MACULAR DEGENERATION

Welcome to Today's Virtual Symposium for Investors and Analysts

Forward-looking statements

The presentations today include forward-looking statements of IVERIC bio, Inc. (the "Company"). Any statements about the Company's future expectations, plans and prospects constitute forward-looking statements for purposes of the safe harbor provisions under the Private Securities Litigation Reform Act of 1995. Forward-looking statements include any statements about the Company's strategy, future operations and future expectations and plans and prospects for the Company, and any other statements containing the words "anticipate," "believe," "estimate," "expect," "intend", "goal," "future", "may", "might," "plan," "predict," "project," "seek," "target," "potential," "will," "would," "could," "should," "continue," and similar expressions. In the presentations today, the Company's forward looking statements include statements about the timing, progress and results of clinical trials, including expectations regarding patient enrollment and retention in GATHER2, the Company's development strategy for Zimura and IC-500, including their potential development in other forms or stages of dry age-related macular degeneration, the Company's hypotheses regarding complement inhibition and inhibition of HtrA1 as mechanisms of action to treat GA and other forms of dry AMD, estimates regarding the number of patients the Company's product candidates are intended to treat, and the utility of Zimura and IC-500. Such forward-looking statements involve substantial risks and uncertainties that could cause the Company's development programs, future results, performance or achievements to differ significantly from those expressed or implied by the forward-looking statements. Such risks and uncertainties include, among others, those related to the progression and duration of the COVID-19 pandemic and responsive measures thereto and related effects on the Company's research and development programs, operations and financial position, the initiation and the progress of research and development programs and clinical trials, availability of data from these programs, expectations for regulatory matters, reliance on clinical trial sites, contract research organizations and other third parties, developments from the Company's competitors and the marketplace for its products, need for additional financing and negotiation and consummation of business development transactions and other factors discussed in the "Risk Factors" section contained in the quarterly and annual reports that the Company files with the Securities and Exchange Commission. Any forward-looking statements represent the Company's views only as of today. The Company anticipates that subsequent events and developments may cause its views to change. While the Company may elect to update these forward-looking statements at some point in the future, the Company specifically disclaims any obligation to do so except as required by law.

Financial disclosures

Frank G. Holz, MD	Grants: Centervue, Ellex, NightStarXOptos Grants and consultant/advisor: Acucela, Allergan, Apellis, Bayer, Bioeq/Formycon, Roche/Genentech, Geuder, Heidelberg Engineering, Iveric Bio, Kanghong, Novartis, Zeiss Consultancy/advisor: Boehringer-Ingelheim, Graybug Vision, LinBioscience, Pixium Vision, Stealth BioTherapeutics, Aerie, Oxurion
Peter K. Kaiser, MD	Consultant: Aerie, Allegro, Allergan, Allgenesis, Alzheon, Annexon Biosciences, AsclepiX, Aviceda, Bayer, Bausch and Lomb, Biogen Idec, Bionic Vision Technologies, Boehringer Ingelheim, Carl Zeiss Meditec, Clearside Biomedical, DelSiTech, DTx Pharma, Duet Therapeutics, Eyevensys, Galecto Biotech, Galimedix, Gemini Therapeutics, Glaukos, Innovent, IRENix, IvericBio, jCyte, Kanaph Therapeutics, Kanghong, Kodiak, LensGen, NGM Biopharmaceuticals, Inc., Novartis, Ocugenix, Oculus, Ocuphire, OcuTerra Therapeutics Inc., Omeros, Opthea, Oxurion, Palatin, Regeneron, RegenxBio, Retinal Sciences, Retrope, Roivant, Samsung Bioepis, Sandoz, Santen, Stealth Biotherapeutics, Sustained Nano Systems, Takeda, Théa, 2020 Onsite
Arshad M. Khanani, MD, MA	Consultant: Adverum, Aerpio, Allergan, Chengdu Kanghong, Dutch Ophthalmic Research Center, Genentech, Inc., Kato, Kodiak, Novartis, Gemini, Graybug, Gyroscope, Opthea, Oxurion, PolyPhotonix, Recens Medical, Regenxbio, Roche Research support: Adverum, Alkahest, Allegro, Allergan, Chengdu Kanghong, Gemini, Genentech, Inc., Gyroscope, Iveric Bio, NGM, Kodiak, Novartis, Opthea, Oxurion, Regenxbio, Recens Medical, Roche Lecture fees: Allergan, Genentech, Novartis
Anat Loewenstein, MD	Consultant: Allergan, Bayer Health Care, Beyeonics, Forsightlabs, Notal Vision, Novartis, Roche
Vas R. Sadda, MD	Consultant: Allergan, Amgen, Iveric, Apellis, Bayer, Merck, 4DMT, Roche/Genentech, Novartis, Oxurion, Regeneron, NightstaRX, Optos, CenterVue, Heidelberg Research instruments: Topcon, Nidek, Carl Zeiss Meditec, Heidelberg, CenterVue, Optos
Trent M. Woodruff, PhD	Consultant: Alexion, Alsonex, Visterra, Clearview, Mabyon, Annexon
Charles C. Wykoff, MD, PhD	Consultant: Adverum, Aerie Pharmaceuticals, Allergan, Allgenesis, Apellis, Arctic Vision, Arrowhead Pharmaceuticals, Bausch + Lomb, Bayer, Bionic Vision Technologies, Chengdu Kanghong Biotechnologies (KHB), Clearside Biomedical, EyePoint Pharmaceuticals, Genentech, Gyroscope, IVERIC Bio, Kato Pharmaceuticals, Kodiak Sciences, Long Bridge Medical, NGM Biopharmaceuticals, Novartis, OccuRx, Ocular Therapeutix, ONL Therapeutics, Opthea Limited, Oxurion, Palatin, PolyPhotonix, RecensMedical, Regeneron, RegenXBio, Roche, SAI MedPartners, Surrozen Takeda, Verana Health Research: Adverum, Aerie Pharmaceuticals, Aldeyra, Alimera Sciences, Allergan, Amgen, Apellis, Asclepix, Bayer, Boehringer Ingelheim, Chengdu Kanghong Biotechnology, Clearside Biomedical, Gemini, Genentech, Graybug Vision, Gyroscope, IONIS Pharmaceutical, iRENIX, IVERIC bio, Kodiak Sciences, LMRI, Neurotech Pharmaceuticals, NGM Biopharmaceuticals, Novartis, Oxurion, RecensMedical, Regeneron, RegenXBio, Roche, SamChunDang Pharm, Taiwan Liposome Company, Xbrane BioPharma Ownership/Stock: ONL Therapeutics, PolyPhotonix, RecensMedical, Visgenx



DRY AGE-RELATED MACULAR DEGENERATION

Welcome to Today's Virtual Symposium for Investors and Analysts

GLENN P. SBLENDORIO

Chief Executive Officer, Iveric Bio



DRY AGE-RELATED MACULAR DEGENERATION

Virtual Symposium for Investors and Analysts

PRAVIN U. DUGEL, MD

President, Iveric Bio



DRY AGE-RELATED MACULAR DEGENERATION

Agenda & Overview

DHAVAL B. DESAI, PharmD

Chief Development Officer, Iveric Bio

Dry Age-Related Macular Degeneration

A Virtual Symposium for Investors and Analysts

June 18, 2021

10:00 AM – 12:00 PM (EDT)

AGENDA

10:00 – 10:04

Introduction & Patient Video

10:04 – 10:06

Welcome

Glenn P. Sblendorio

10:06 – 10:11

Introduction

Pravin U. Dugel, MD

10:11 – 10:12

Introduction of chief development officer

Pravin U. Dugel, MD

10:12 – 10:15

Introduction to agenda/symposium

Dhaval B. Desai, PharmD

10:15 – 10:25

Geographic atrophy: A physician's perspective

Frank G. Holz, MD

10:25 – 10:35

Complement in GA

Charles C. Wykoff, MD, PhD

10:35 – 10:45

Implications for therapeutic targeting of complement

Trent M. Woodruff, PhD

10:45 – 10:55

GATHER1: 18-month data

Anat Loewenstein, MD

10:55 – 11:05

GATHER2: Trial design and progress

Arshad M. Khanani, MD, MA

11:05 – 11:15

GATHER1: Post-hoc analysis in early AMD

Vas R. Sadda, MD

11:15 – 11:25

Expanding beyond complement

Peter K. Kaiser, MD

11:25 – 11:55

Panel discussion

All

11:55 – 12:00

Closing remarks

Pravin U. Dugel, MD



GEOGRAPHIC ATROPHY

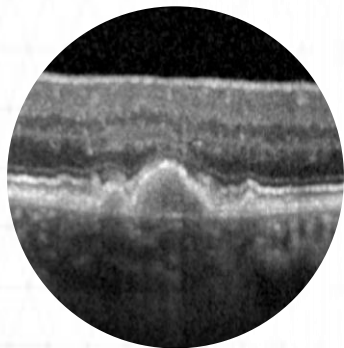
A Physician's Perspective

FRANK G. HOLZ, MD

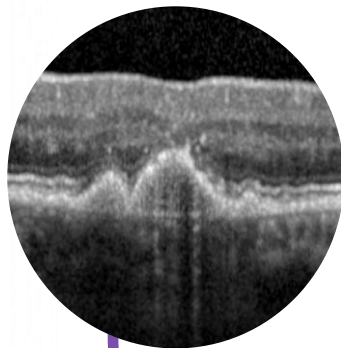
Professor and Chair of the Department of Ophthalmology
The University of Bonn, Germany

Pathway of AMD disease progression

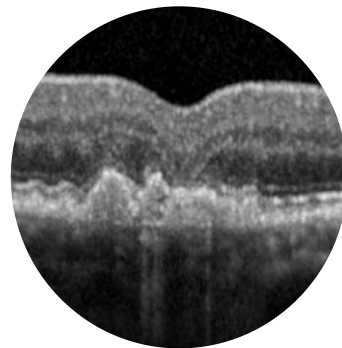
Medium drusen
(Early AMD)



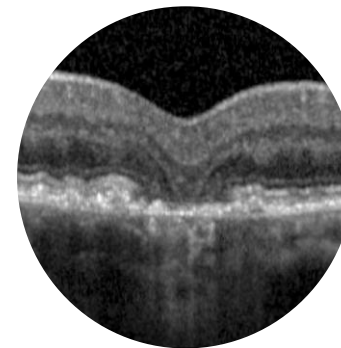
Large drusen
(Intermediate AMD)



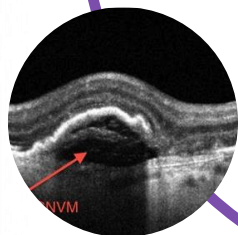
RPE alterations



Atrophy
(Late AMD)

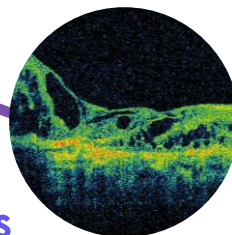


CNV
(Late AMD)



Anti-VEGF therapy

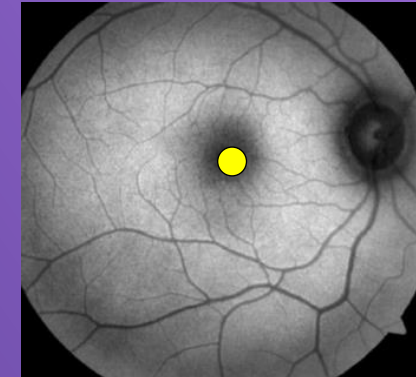
Fibrosis



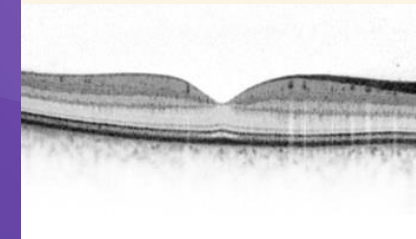
GA can cause severe vision loss

- ✓ GA is defined by
 - Loss of photoreceptors, RPE, and choriocapillaris
 - Sharply demarcated atrophic lesions of the outer retina
 - Irreversible loss of visual function
- ✓ The rate and nature of GA progression are unpredictable and highly variable across patients
- ✓ The goal of treatment is to protect the fovea
 - Once retinal cells in the fovea die, there is no way to restore the lost vision

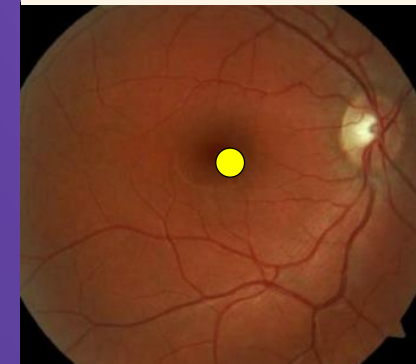
Normal Eye



FUNDUS
AUTOFLUORESCENCE

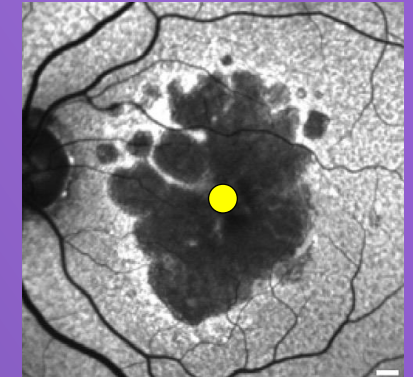


OPTICAL COHERENCE
TOMOGRAPHY

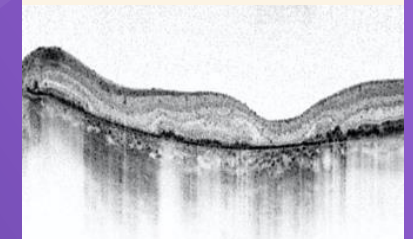


COLOR FUNDUS
PHOTOGRAPHY

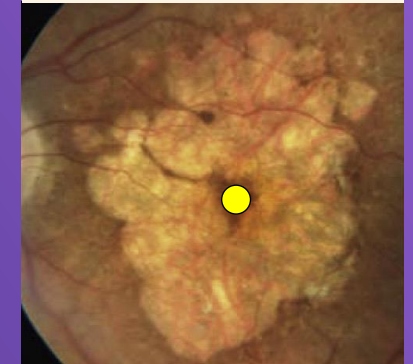GA



FUNDUS
AUTOFLUORESCENCE

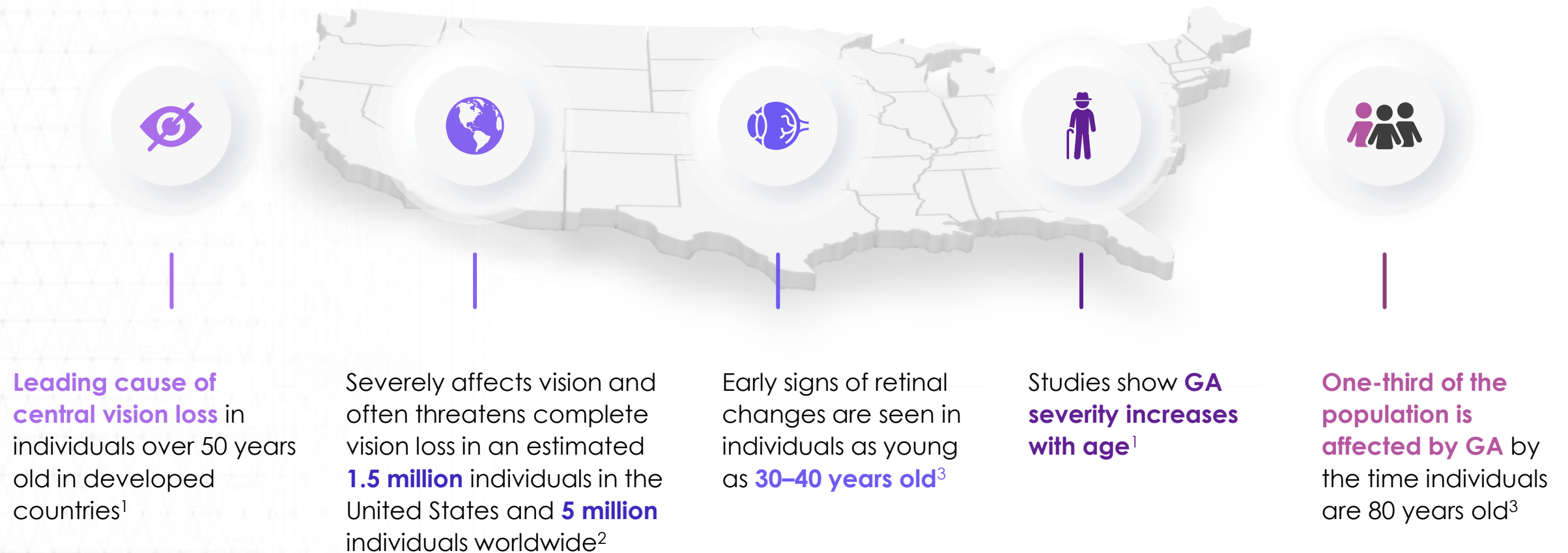


OPTICAL COHERENCE
TOMOGRAPHY



COLOR FUNDUS
PHOTOGRAPHY

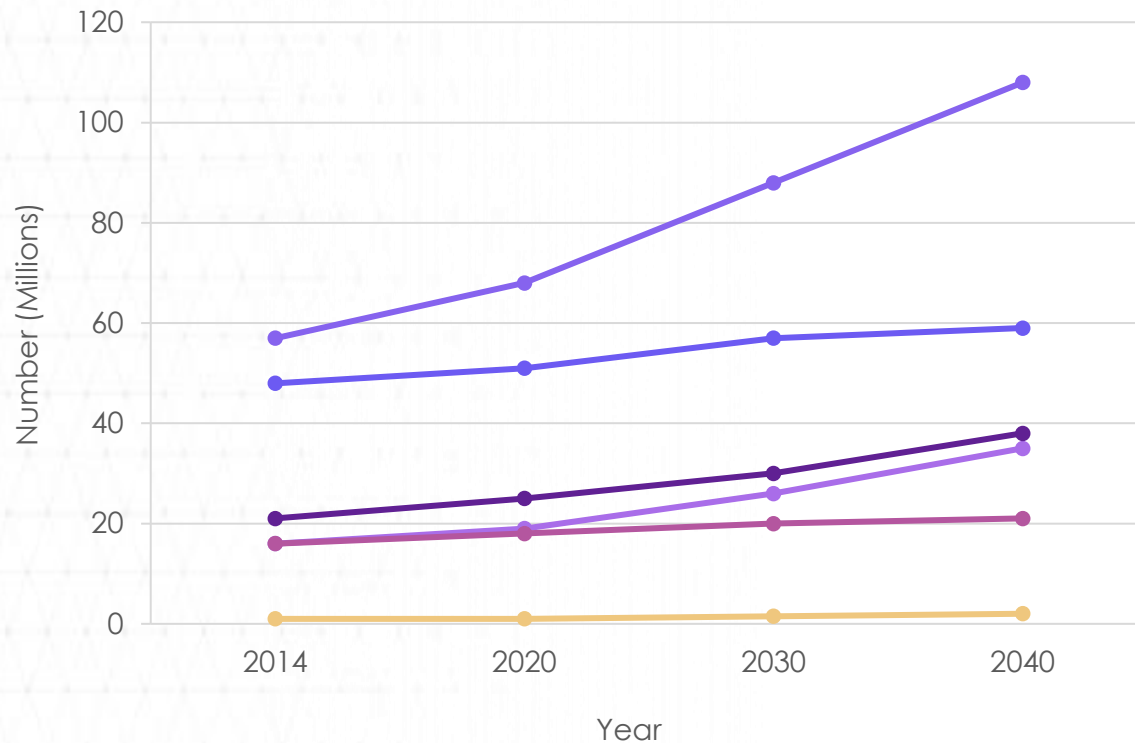
GA severely impacts vision in ~1.5 million patients in the US alone



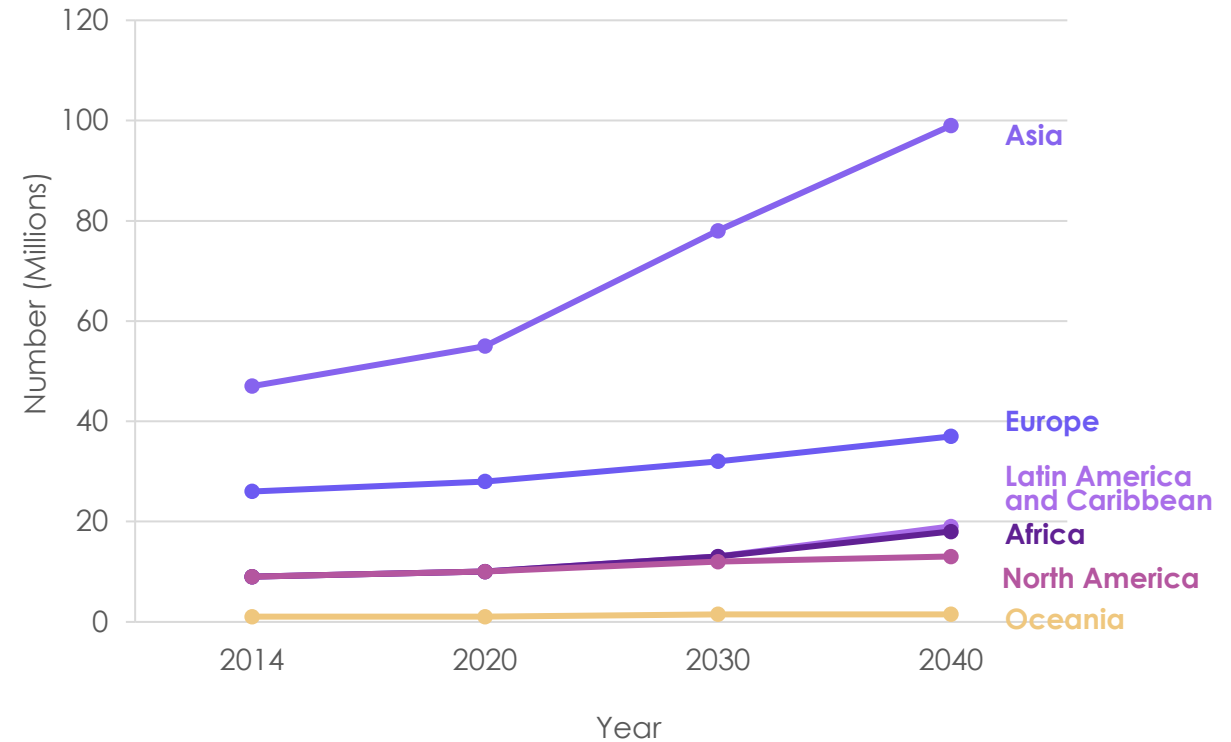
AMD is projected to increase in global prevalence

Projected number of individuals with AMD by region¹

Early AMD

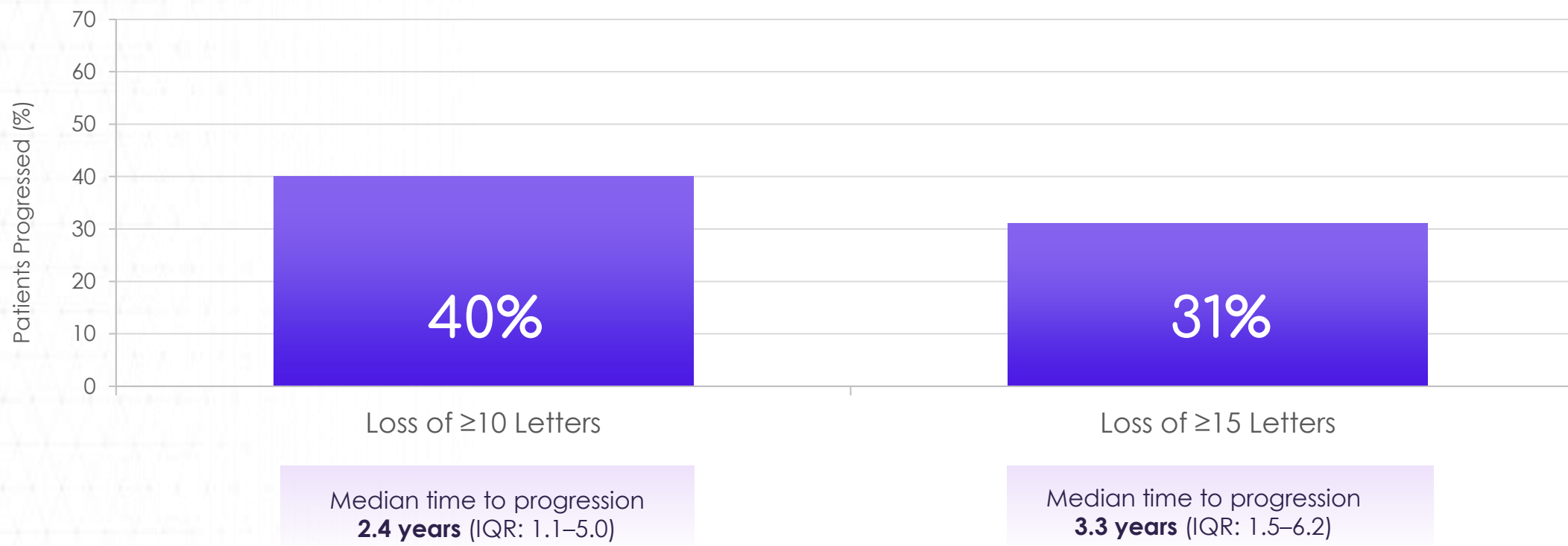


Late AMD



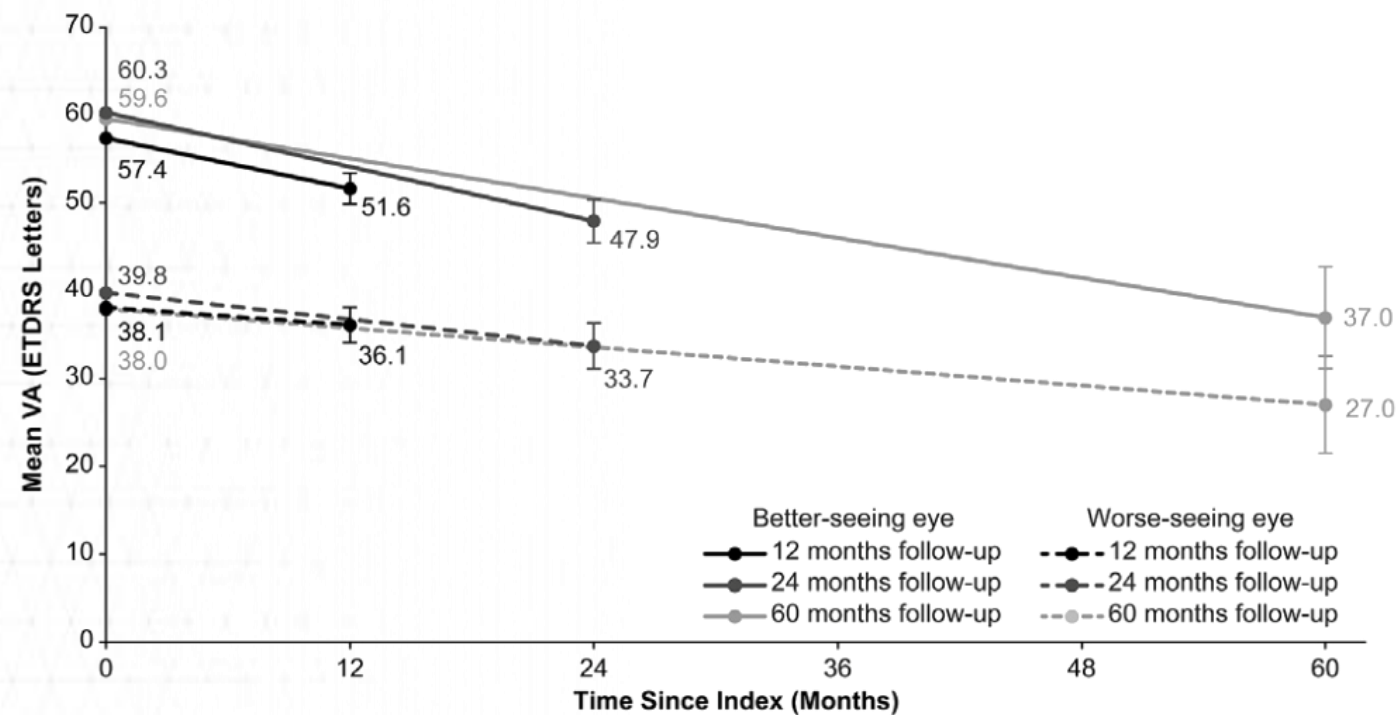
GA progression leads to visual impairment

Visual acuity loss in worse-seeing eye



Generally, decline in the better-seeing eye is faster

Change in mean visual acuity from baseline in the worse-seeing study eye and better-seeing fellow eye^{1,2}



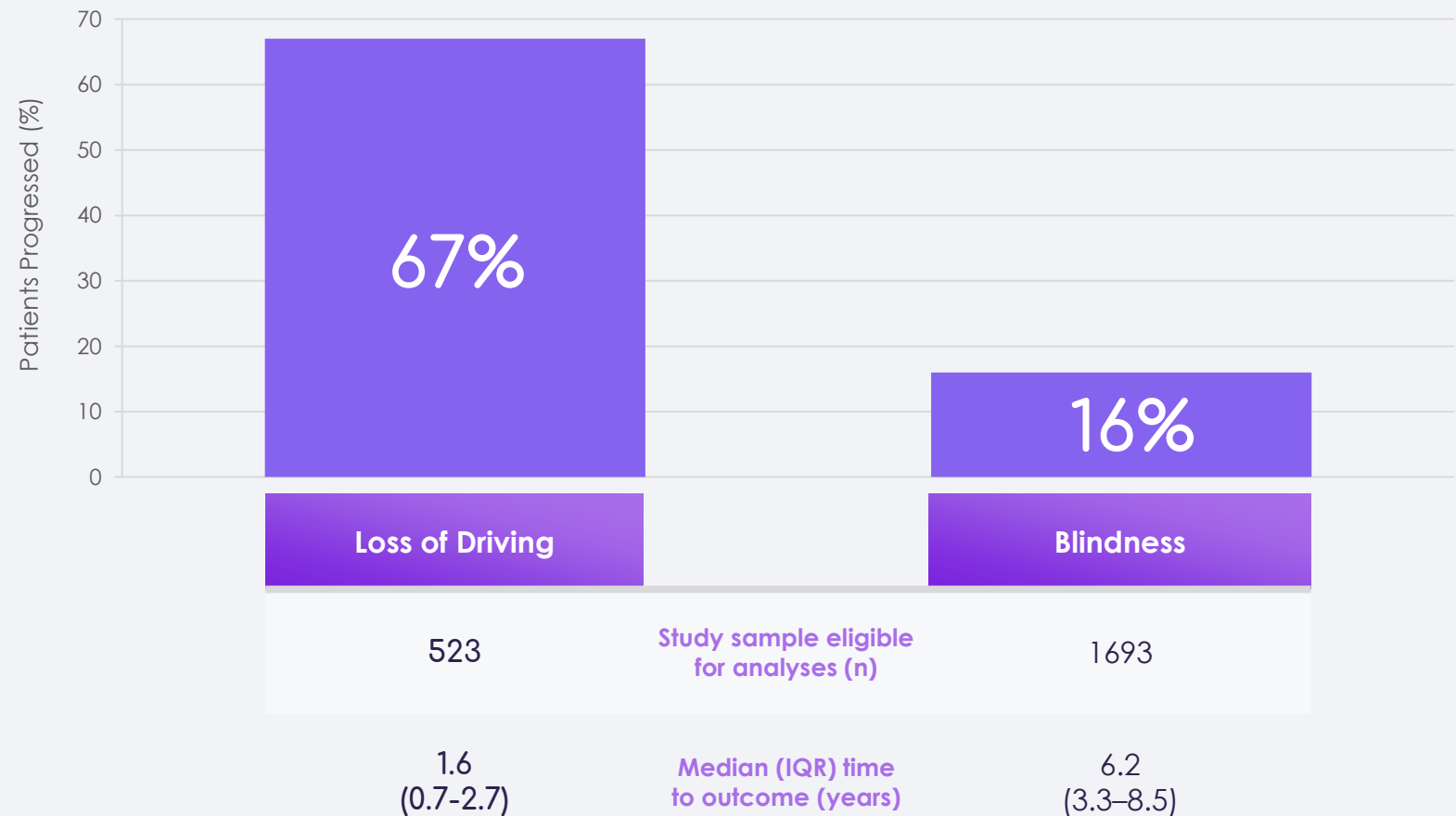
Mean vision loss (ETDRS letters)

	<div>✓</div> Better-seeing eye	<div>✗</div> Worse-seeing eye
1 year	-5.7	-2.0
2 years	-12.4	-6.1
5 years	-22.6	-10.9

1. Chakravarthy U, Bailey CC, Johnston RL, et al. Characterizing disease burden and progression of geographic atrophy secondary to age-related macular degeneration. Ophthalmology. 2018;125(6):842-849. doi:10.1016/j.ophtha.2017.11.036. 2. Rosenfeld PJ. Preventing the growth of geographic atrophy: an important therapeutic target in age-related macular degeneration. Ophthalmology. 2018;125(6):794-795. doi:10.1016/j.ophtha.2018.02.027.

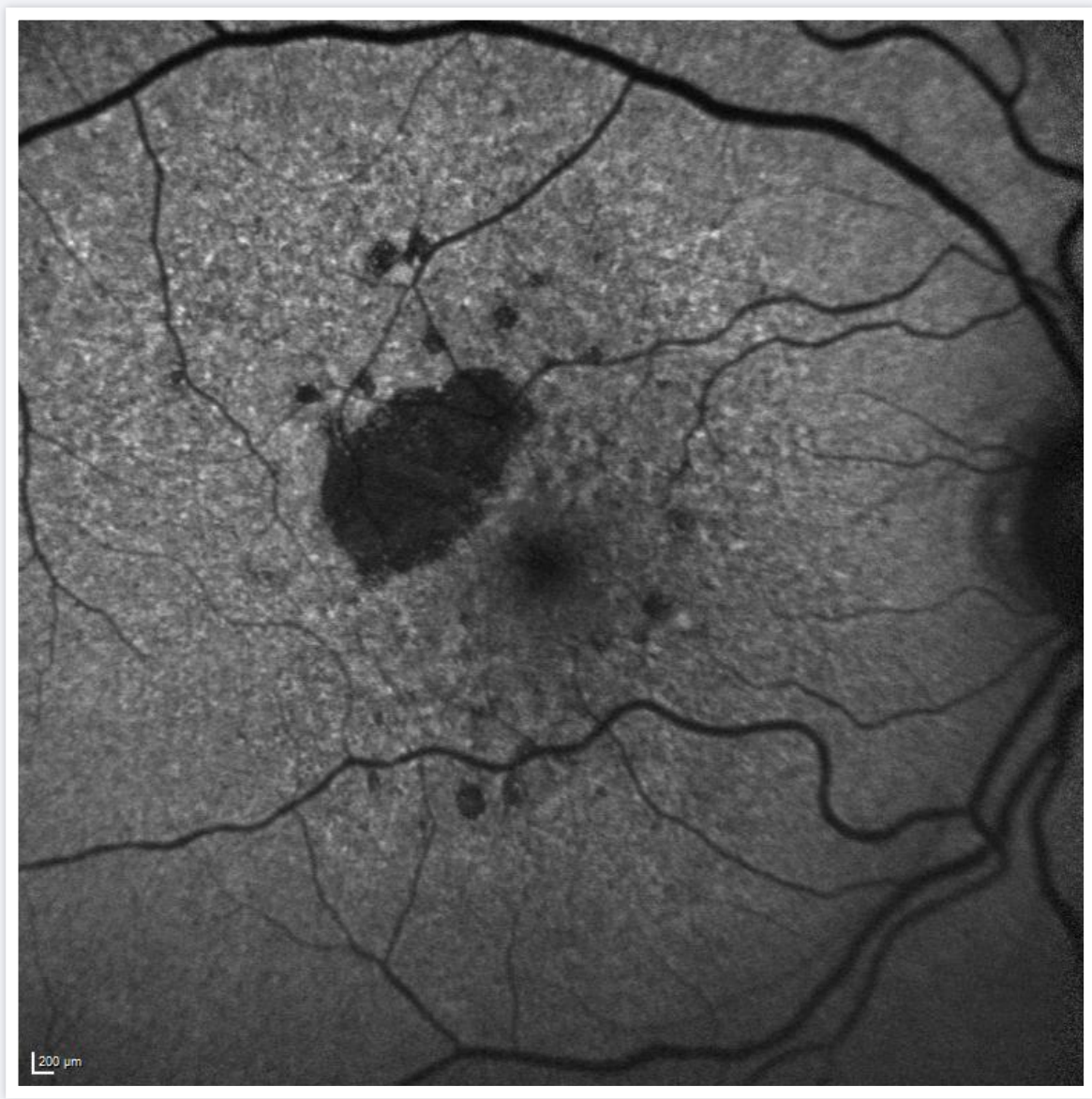
Functional vision loss leads to loss of independence and ability to complete tasks of daily living, such as driving

Many patients lose the ability to perform daily tasks and can progress to legal blindness



GA progression
is relentless

Courtesy: Frank Holz, MD



Key takeaways

- ✓ GA is the largest unmet need in retina with 5 million affected worldwide with no currently approved treatments
- ✓ This serious disease is one of the largest causes of vision loss or blindness
- ✓ Patients with GA may struggle with everyday activities, such as reading, cooking, driving, and recognizing faces
- ✓ Our goal is to treat disease early and maintain visual function for as long as possible



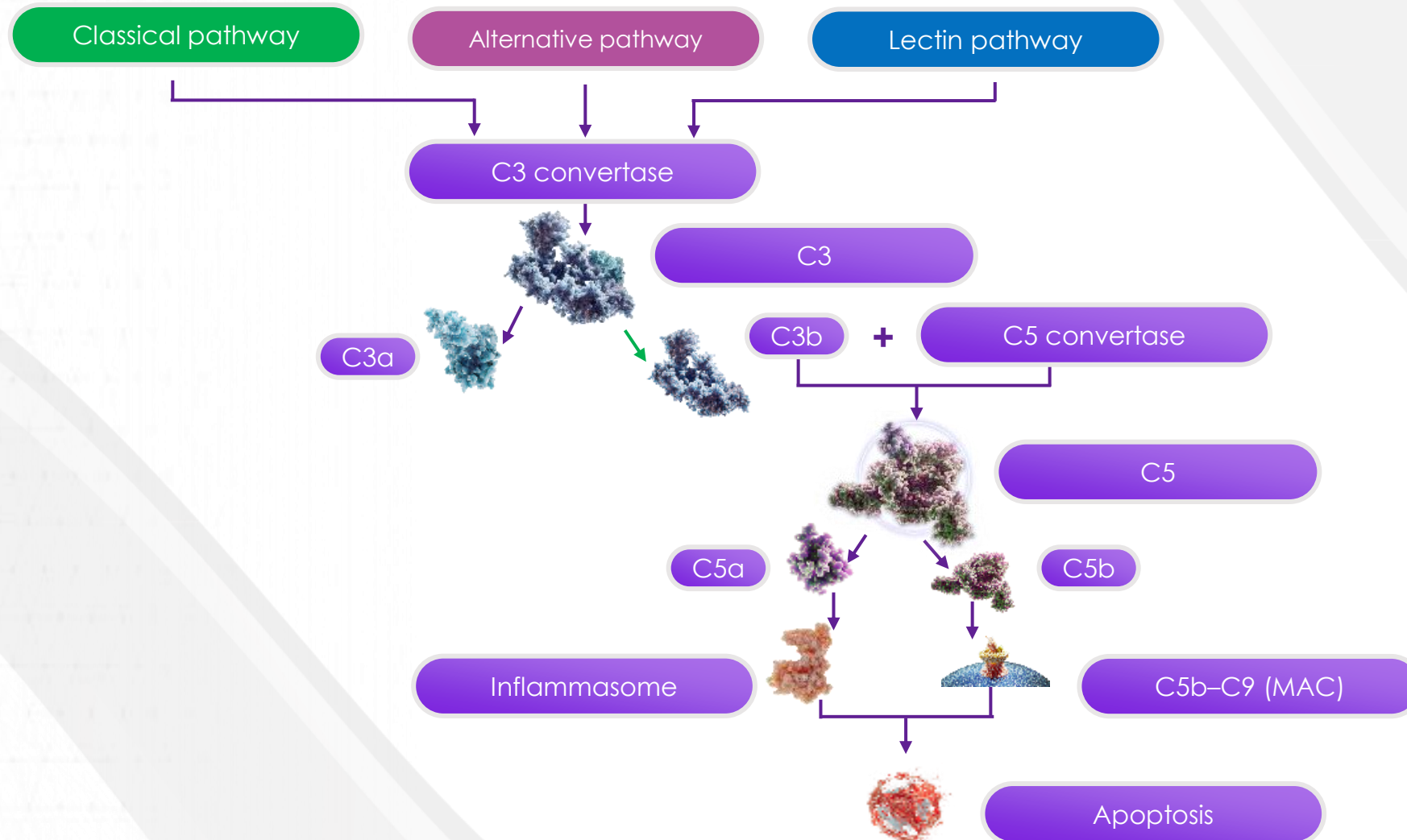
COMPLEMENT IN GA

What We Know About the Role of Complement in the Pathogenesis of GA

CHARLES C. WYKOFF, MD, PHD

Retina Consultants of Texas, Director of Research
Greater Houston Retina Research Foundation, Houston, TX

Activated complement leads to inflammation and cell death



Why complement as a target for GA?

Three key factors have pointed us in the direction of complement:

- Genetics
- Histopathology
- Clinical trial data

Complement Activation Levels Are Related to Disease Stage in AMD

Thomas J. Heesterbeek,¹ Yara T. E. Lechanteur,¹ Laura Lorés-Motta,^{1,2} Tina Schick,³ Mohamed R. Doha,⁴ Lebriz Altay,³ Sandra Liakopoulos,³ Dzenita Smailhodzic,¹ Anneke I. den Hollander,^{1,2} Carel B. Hoyng,¹ Eiko K. de Jong,¹ and B. Jeroen Klevering¹

¹Department of Ophthalmology, Donders Institute for Brain, Cognition and Behaviour, Radboud University Medical Center, Nijmegen, the Netherlands

²Department of Human Genetics, Donders Institute for Brain, Cognition and Behaviour, Radboud University Medical Center, Nijmegen, the Netherlands

³Department of Ophthalmology, University Hospital of Cologne, Cologne, Germany

⁴Department of Nephrology, Leiden University Medical Center, Leiden, the Netherlands

THE PATHOPHYSIOLOGY OF GEOGRAPHIC ATROPHY SECONDARY TO AGE-RELATED MACULAR DEGENERATION AND THE COMPLEMENT PATHWAY AS A THERAPEUTIC TARGET

DAVID S. BOYER, MD,* URSULA SCHMIDT-ERFURTH, MD,† MENNO VAN LOOKEREN CAMPAGNE, PhD,‡ ERIN C. HENRY, PhD,‡ CHRISTOPHER BRITTAIN, MBBS§

Complement System in Pathogenesis of AMD: Dual Player in Degeneration and Protection of Retinal Tissue

Milosz P. Kawa,¹ Anna Machalinska,^{2,3} Dorota Roginska,¹ and Boguslaw Machalinski¹

¹ Department of General Pathology, Pomeranian Medical University, Al. Powstancow Wlkp. 72, 70-111 Szczecin, Poland

² Department of Ophthalmology, Pomeranian Medical University, Al. Powstancow Wlkp. 72, 70-111 Szczecin, Poland

³ Department of Histology and Embryology, Pomeranian Medical University, Al. Powstancow Wlkp. 72, 70-111 Szczecin, Poland

Genetic studies link complement activation to AMD

- Complement abnormalities are strongly associated with the development of AMD
- In individuals who are homozygous for the risk allele, the likelihood of AMD is increased by a factor of 7.4

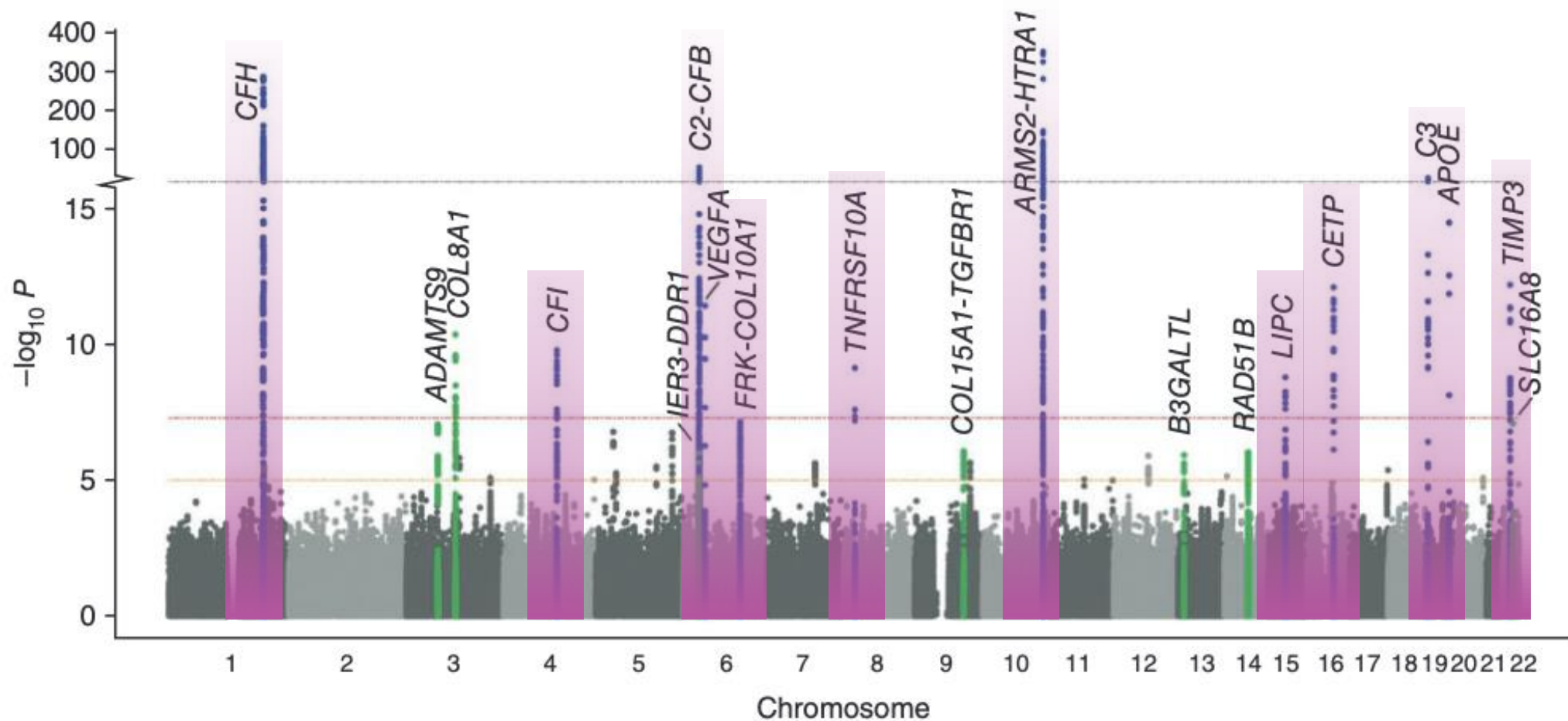
Analysis of Risk Alleles and Complement Activation Levels in Familial and Non-Familial Age-Related Macular Degeneration

Nicole T. M. Saksens¹, Yara T. E. Lechanteur¹, Sanne K. Verbakel¹, Joannes M. M. Groenewoud², Mohamed R. Daha³, Tina Schick⁴, Sascha Fauser⁴, Camiel J. F. Boon^{1,5}, Carel B. Hoyng¹, Anneke I. den Hollander^{1,6*}

Genome-Wide Association Studies Identify Disease Mechanisms in Age-Related Macular Degeneration

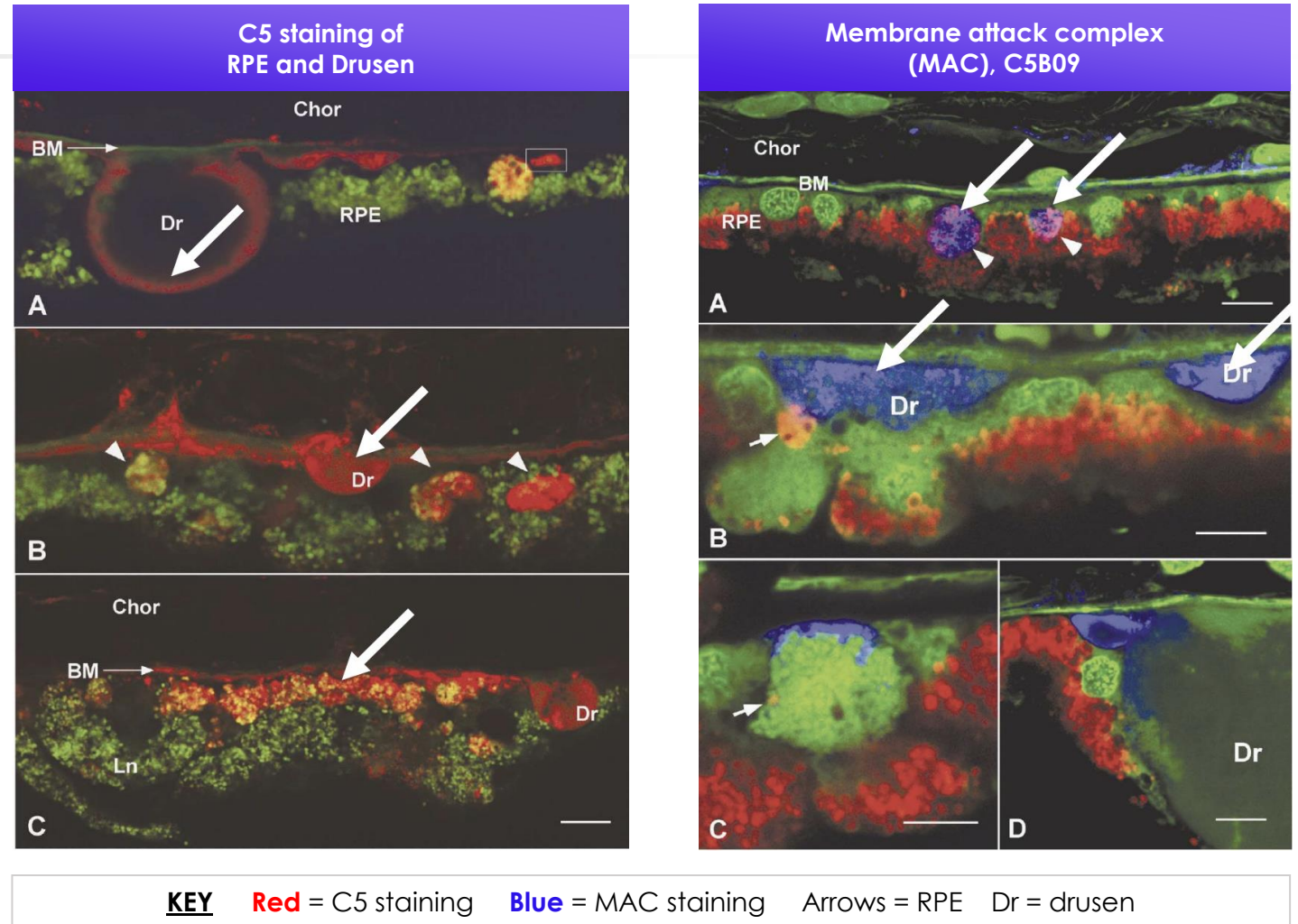
Alan F. Wright, MBChB, PhD,¹ - *Edinburgh, United Kingdom*
Paul N. Barlow, PhD² - *Edinburgh, United Kingdom*

GWAS reveal numerous complement factors that are associated with AMD



Histopathologic evidence of activated complement in eyes with AMD

Evidence from donor eyes points to the fact that activated complement is present in eyes with early AMD



Recent positive clinical trial results in humans

Multiple approaches to inhibiting the complement pathway have shown positive results in GA

Complement C3 Inhibitor Pegcetacoplan for Geographic Atrophy Secondary to Age-Related Macular Degeneration

A Randomized Phase 2 Trial

David S. Liao, MD,¹ Federico V. Grossi, MD, PhD,² Delphine El Mehdi, PhD,² Monica R. Gerber, MD, PhD,² David M. Brown, MD,³ Jeffrey S. Heier, MD,⁴ Charles C. Wykoff, MD, PhD,⁵ Lawrence J. Singerman, MD,⁶ Prema Abraham, MD,⁷ Felix Grassmann, PhD,^{8,9} Peter Nuernberg, PhD,¹⁰ Bernhard H.F. Weber, PhD,⁸ Pascal Deschatelets, PhD,² Robert Y. Kim, MD,² Carol Y. Chung, PhD,² Ramiro M. Ribeiro, MD, PhD,² Mohamed Hamdani, MS,² Philip J. Rosenfeld, MD, PhD,¹¹ David S. Boyer, MD,¹² Jason S. Slakter, MD,^{13,14} Cedric G. Francois, MD, PhD²

C5 Inhibitor Avacincaptad Pegol for Geographic Atrophy Due to Age-Related Macular Degeneration

A Randomized Pivotal Phase 2/3 Trial

Glenn J. Jaffe, MD,¹ Keith Westby, MBA,² Karl G. Csaky, MD, PhD,³ Jordi Monés, MD, PhD,⁴ Joel A. Pearlman, MD, PhD,⁵ Sunil S. Patel, MD, PhD,⁶ Brian C. Joondeph, MD, MPS,⁷ John Randolph, MD,⁸ Harvey Masonson, MD,² Kourous A. Rezaei, MD²

Key takeaways

- ✓ Complement abnormalities are strongly associated with AMD
- ✓ An ever-growing body of complement system genetic markers for AMD are being identified
- ✓ Histopathological studies provide further evidence of complement activation in AMD
- ✓ Recent clinical trial data support the link between complement inhibition and slowing of GA progression



IMPLICATIONS FOR THERAPEUTIC TARGETING OF COMPLEMENT

The Importance of Receptor Signaling: C5 vs C3

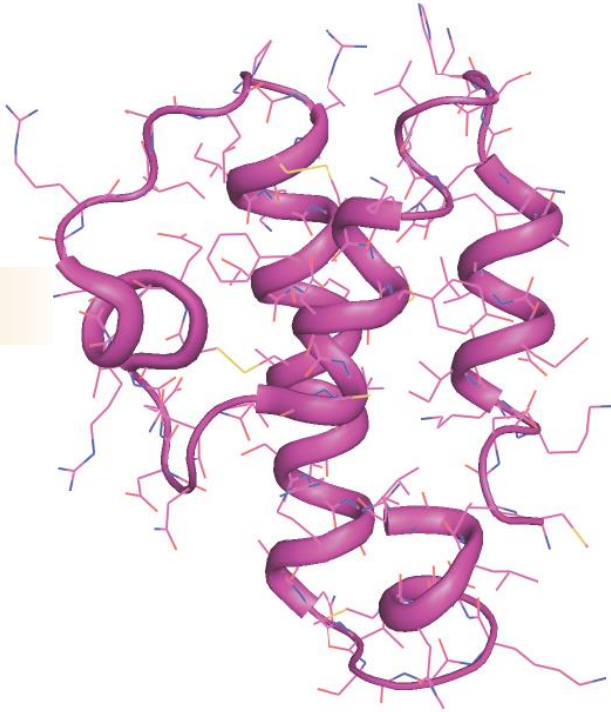TRENT M. WOODRUFF, PhD

Professor of Pharmacology
The University of Queensland, Brisbane, Australia

C5a and C3a have different physiologic functions

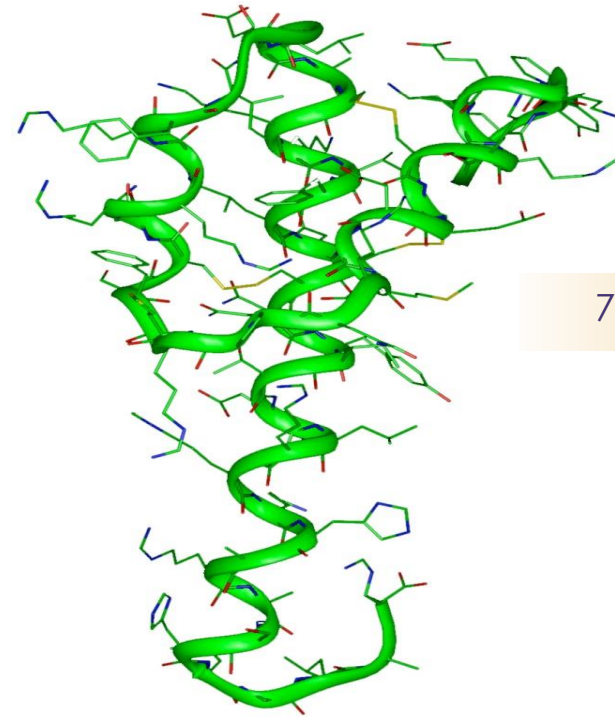
C5a

74aa



C3a

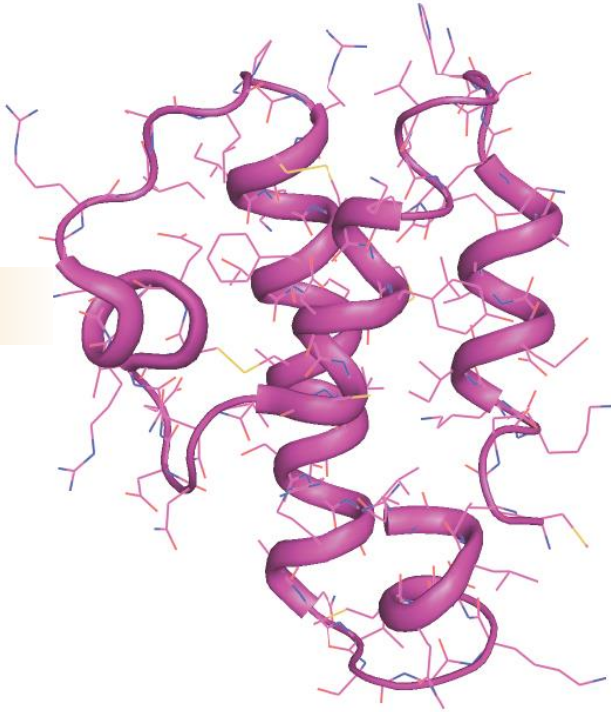
77aa



C5a and C3a have different physiologic functions

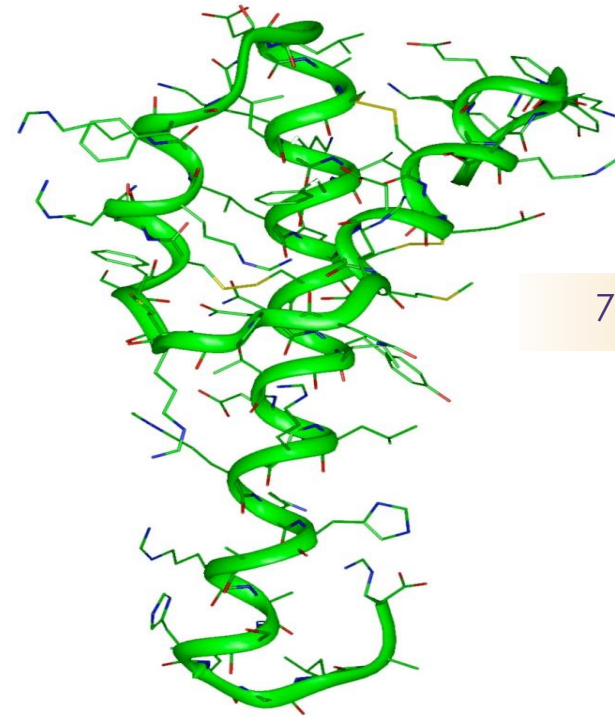
C5a – Pro-inflammatory

74aa



C3a

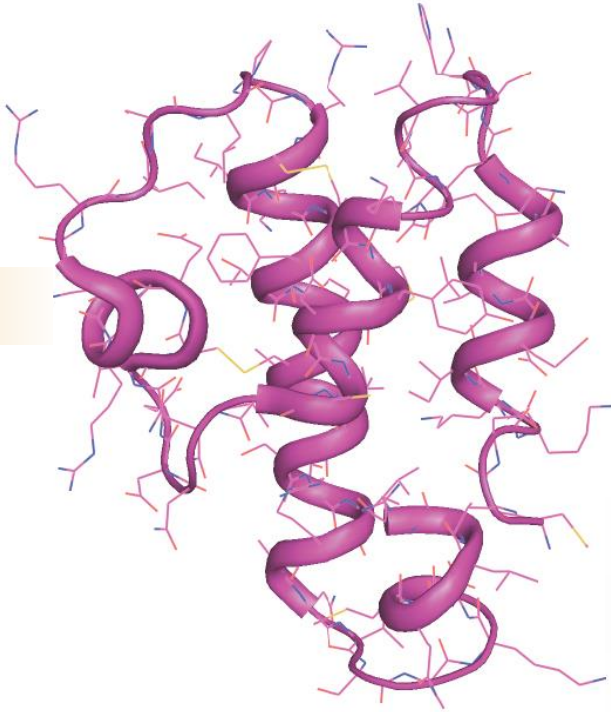
77aa



C5a and C3a have different physiologic functions

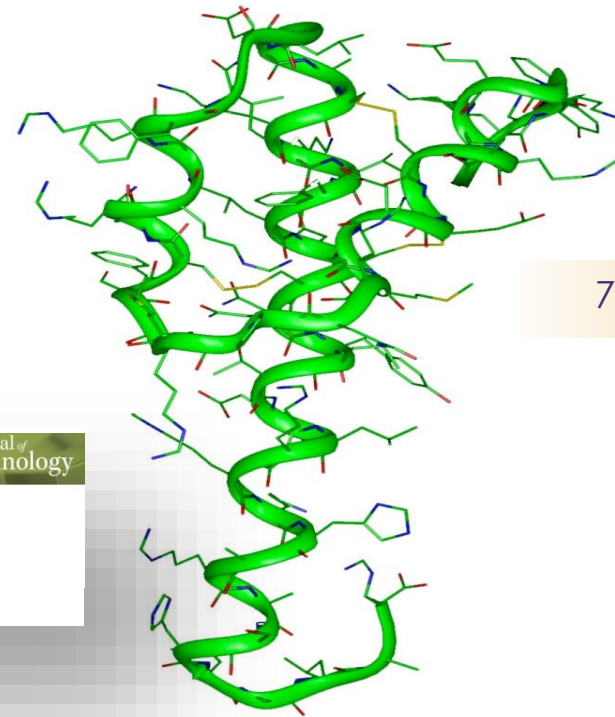
C5a – Pro-inflammatory

74aa



C3a – Pro/Anti-inflammatory

77aa



Brief Reviews

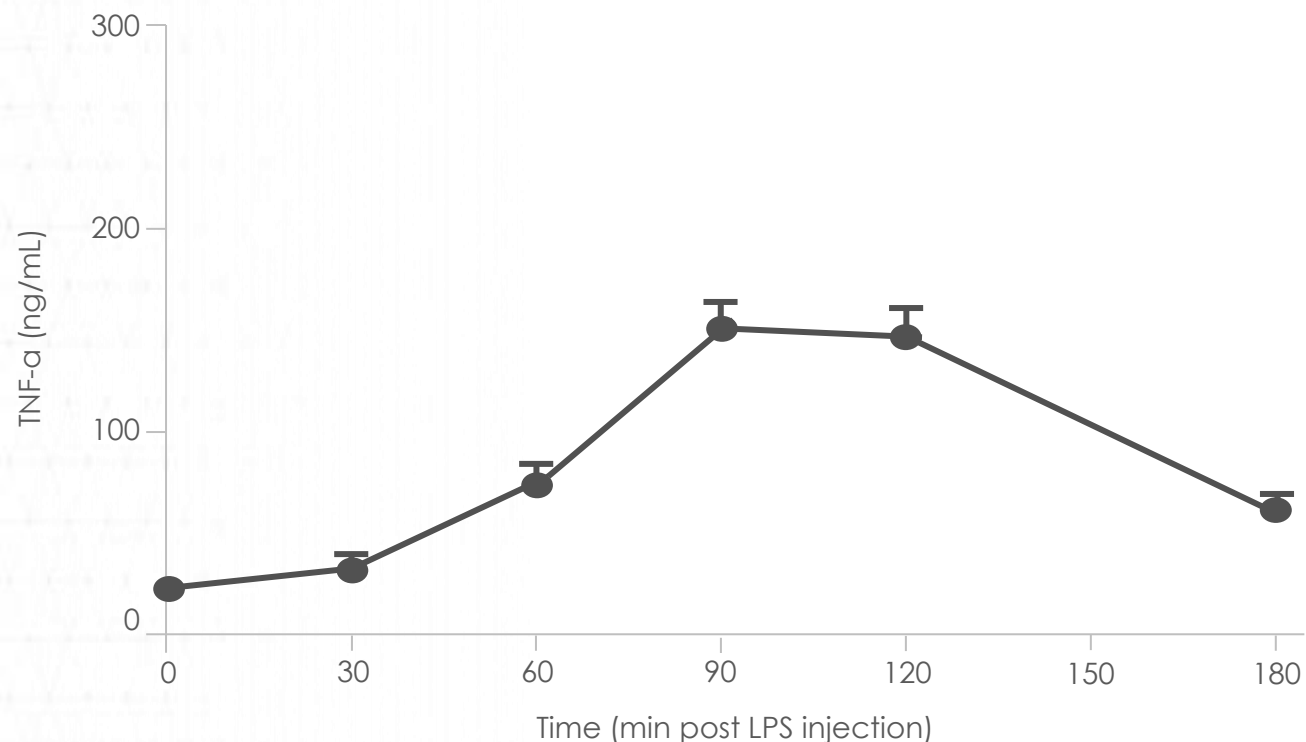
The Journal of
Immunology

Is the Complement Activation Product C3a a Proinflammatory Molecule? Re-evaluating the Evidence and the Myth

Liam G. Coulthard and Trent M. Woodruff

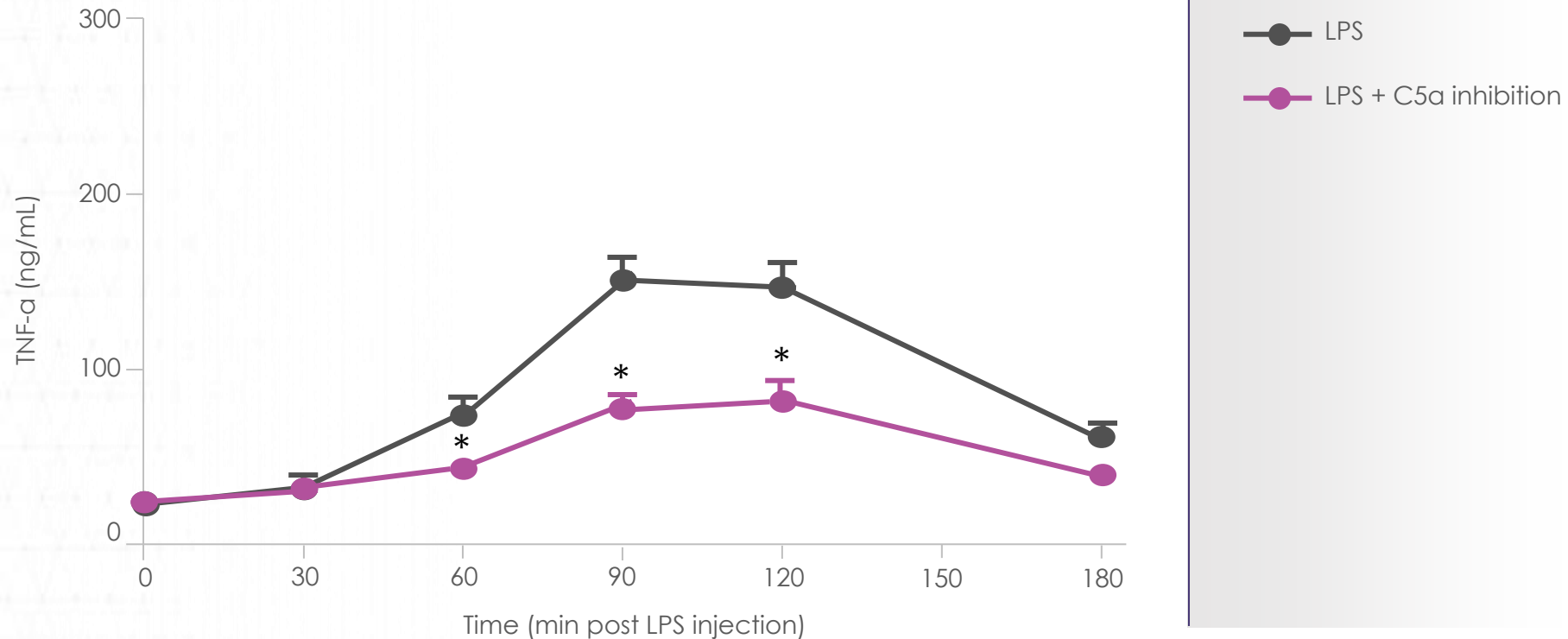
C5a and C3a: Opposing roles in an inflammatory model

Septic Shock | LPS-induced TNF- α release *in vivo*



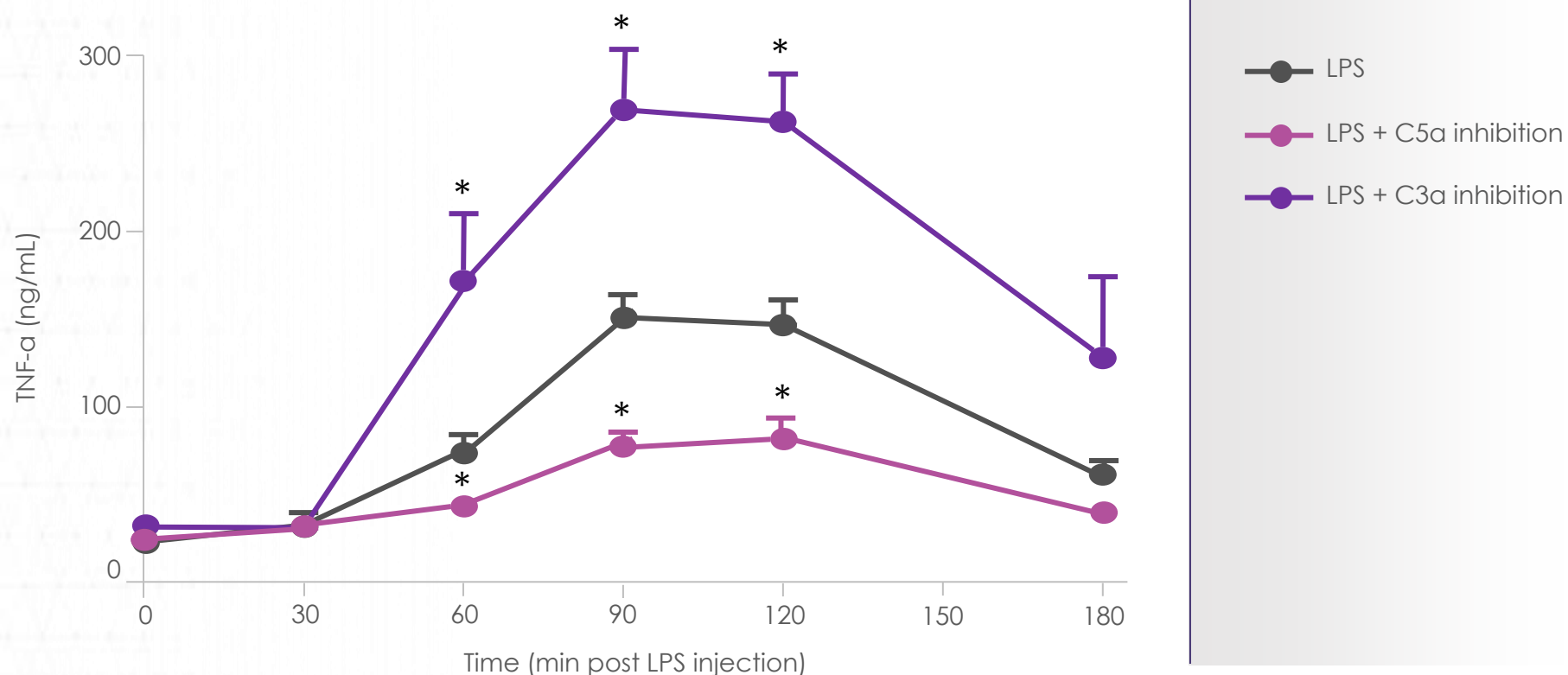
C5a and C3a: Opposing roles in an inflammatory model

Septic Shock | LPS-induced TNF- α release *in vivo*



C5a and C3a: Opposing roles in an inflammatory model

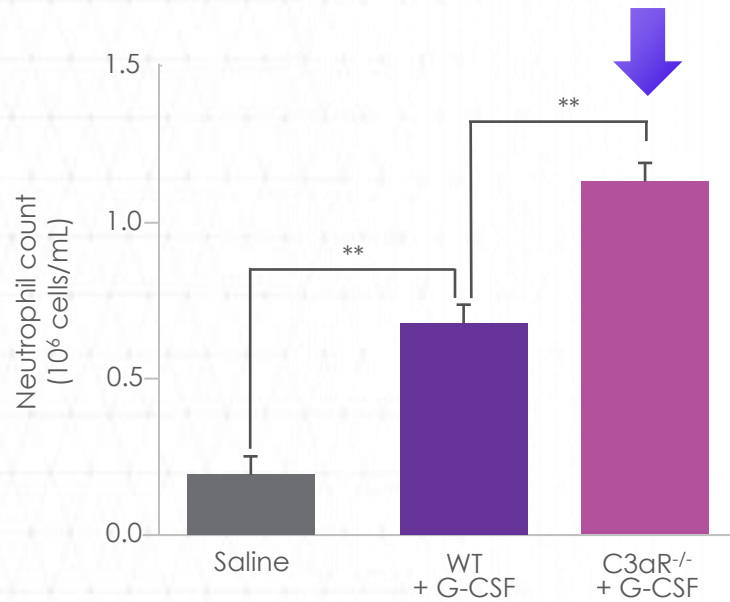
Septic Shock | LPS-induced TNF- α release *in vivo*



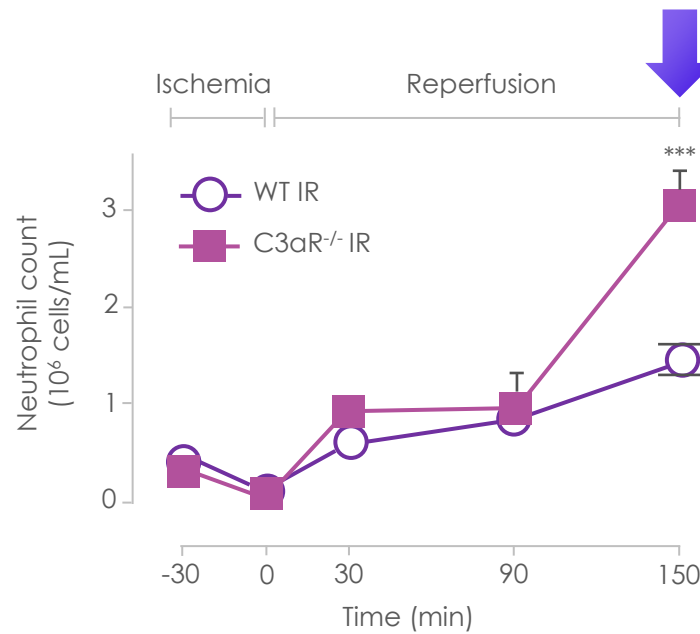
C3a receptor inhibition worsens response in neutrophil activation models

C3a receptors prevent neutrophil mobilization and subsequent tissue infiltration

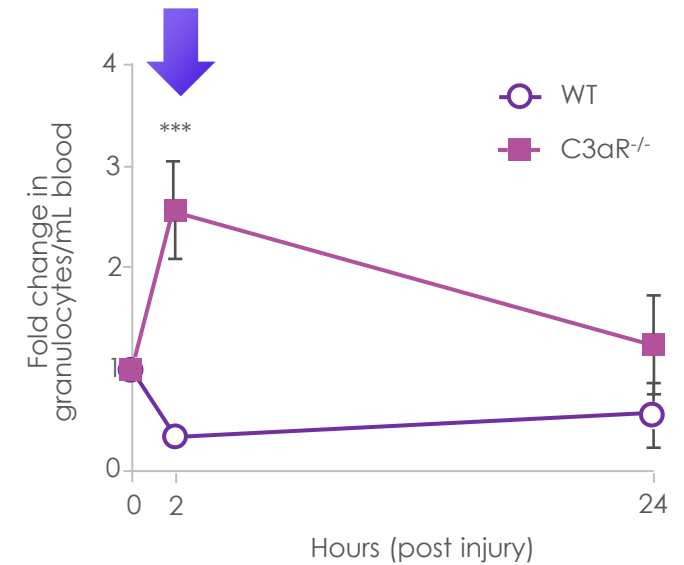
G-CSF



Intestinal I/R

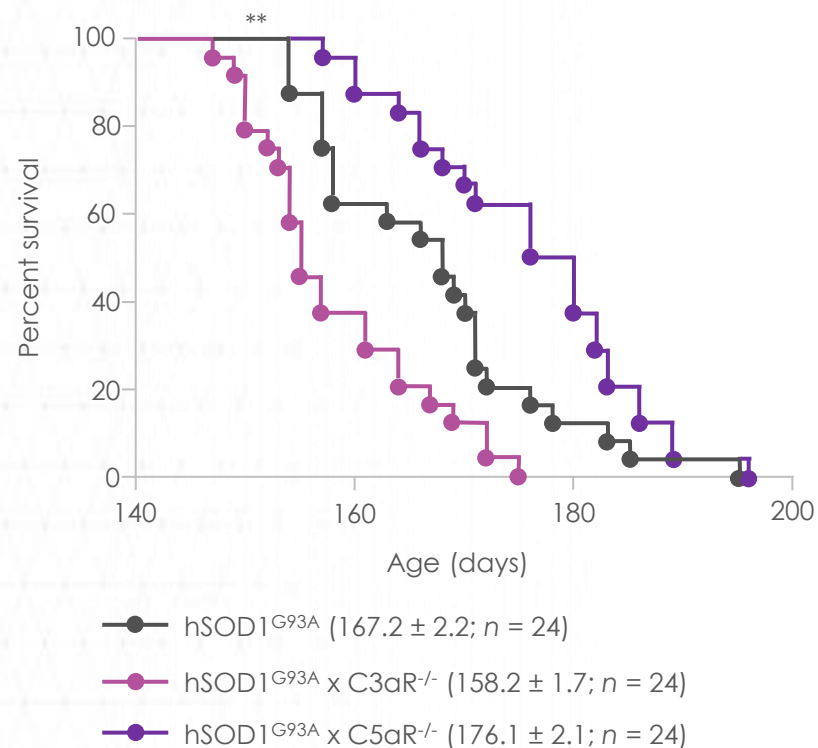


Spinal cord injury



C5a receptor knockout improves survival in neurodegenerative model

Survival



Genetic absence of **C5aR**
improves survival in SOD1^{G93A} mice



Genetic absence of **C3aR**
worsens survival in SOD1^{G93A} mice

Physiologic function of C3 in the eye

iC3b, a fragment of C3, is important in the normal opsonization of apoptotic photoreceptors via CR3

Knockout of CR3 accelerates photoreceptor degeneration in a mouse model of retinitis pigmentosa



C3 fragment–CR3 signaling may be protective in the eye

Key takeaways

- ✓ C5a is pro-inflammatory and has distinct functions from C3a in multiple models
- ✓ Inhibition of C5a showed a reduction in inflammatory response and improvement in survival compared to inhibition of C3a
- ✓ C3 receptor signaling may be important in the normal physiologic function of the eye
- ✓ Blockade of C3 may prevent the beneficial activities of downstream signaling



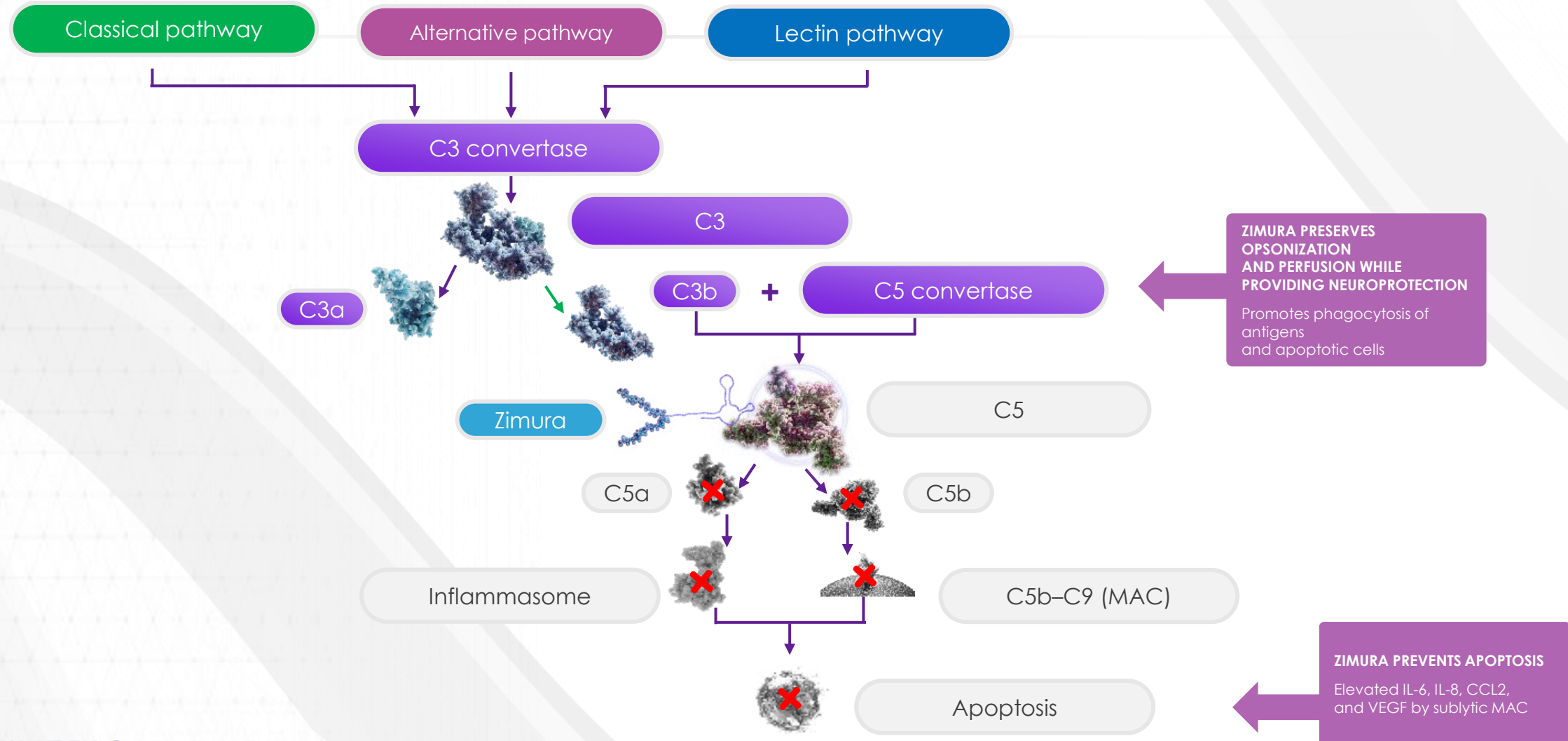
ZIMURA® REDUCES THE RATE OF GEOGRAPHIC ATROPHY GROWTH

18-Month Results From the GATHER1 Clinical Trial

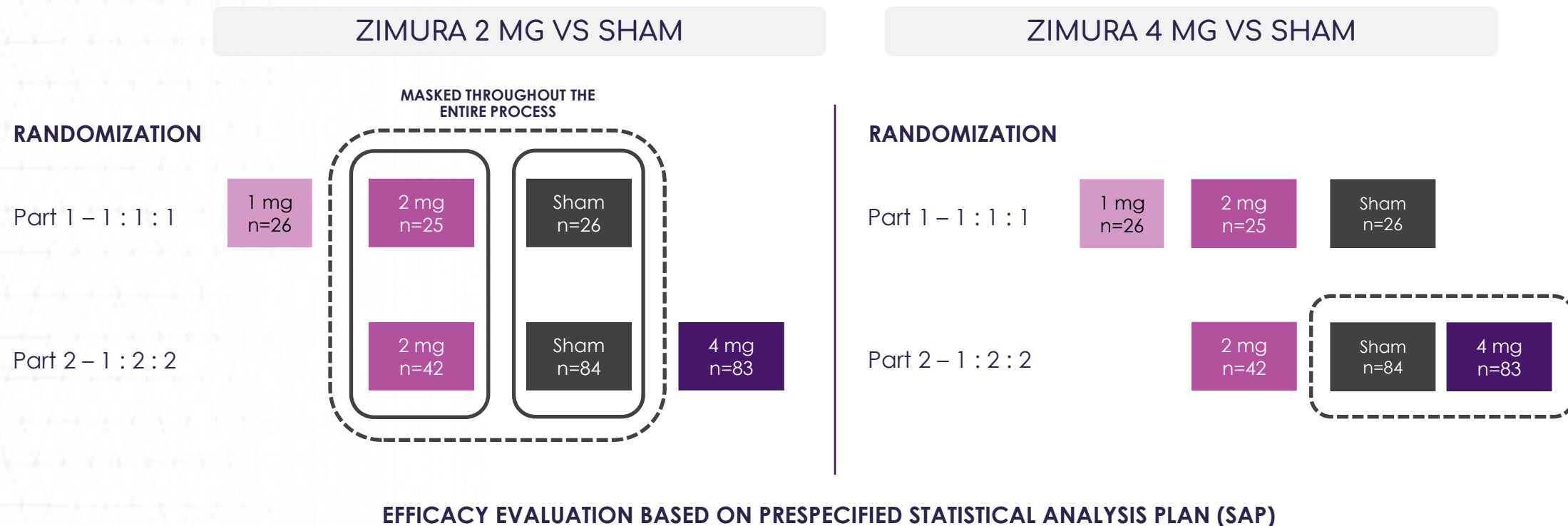
ANAT LOEWENSTEIN, MD

Director, Division of Ophthalmology, Vice Dean
Tel Aviv Medical Center, Tel Aviv University

Zimura targets C5, inhibiting the harmful effects of the complement cascade



Randomization and trial design



- Zimura 2 mg vs sham: Subjects randomized from Part 1 were combined with subjects randomized from Part 2, where the analysis included a regression factor by part

- Zimura 4 mg vs sham: Only based on subjects randomized in Part 2

Baseline patient characteristics were well balanced across the groups

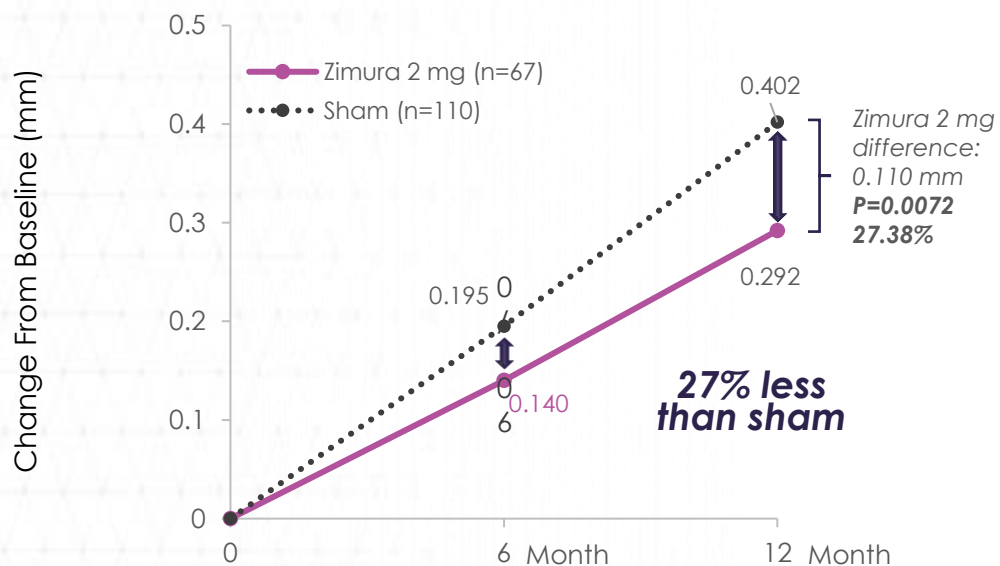
	Zimura 2 mg (n=67)	Sham 2 mg (n=110)	Zimura 4 mg (n=83)	Sham 4 mg (n=84)
Mean age, years (SD)	78.8 (10.2)	78.2 (8.8)	79.2 (8.3)	78.2 (9.0)
Female, no. (%)	45 (67.2%)	79 (71.8%)	58 (69.9%)	61 (72.6%)
Caucasian, no. (%)	67 (100%)	107 (97.3%)	82 (98.8%)	82 (97.6%)
Active smoker, no. (%)	25 (37.3%)	36 (32.7%)	26 (31.3%)	29 (34.5%)
Non-subfoveal GA, no. (%)	62 (92.5%)	104 (94.5%)	81 (97.6%)	82 (97.6%)
Mean total GA area, mm ² (SD)	7.33 (3.79)	7.42 (3.84)	7.90 (4.18)	7.45 (3.89)
Mean square-root GA area, mm (SD)	2.62 (0.70)	2.63 (0.70)	2.72 (0.73)	2.64 (0.71)
Bilateral GA, no. (%)	67 (100%)	108 (98.2%)	83 (100%)	83 (98.8%)
Hyperautofluorescence, µm (%)	66 (98.5%)	109 (99.1%)	82 (98.8%)	83 (98.8%)
Mean BCVA, letters (SD)	70.2 (10.0)	69.0 (10.4)	69.5 (9.8)	68.3 (11.0)
Mean low-luminance BCVA, letters (SD)	36.7 (21.1)	34.5 (19.3)	36.8 (20.9)	33.9 (18.8)
Low-luminance deficit, letters	33.5	34.5	32.7	34.4

GATHER 1 Achieved primary endpoint

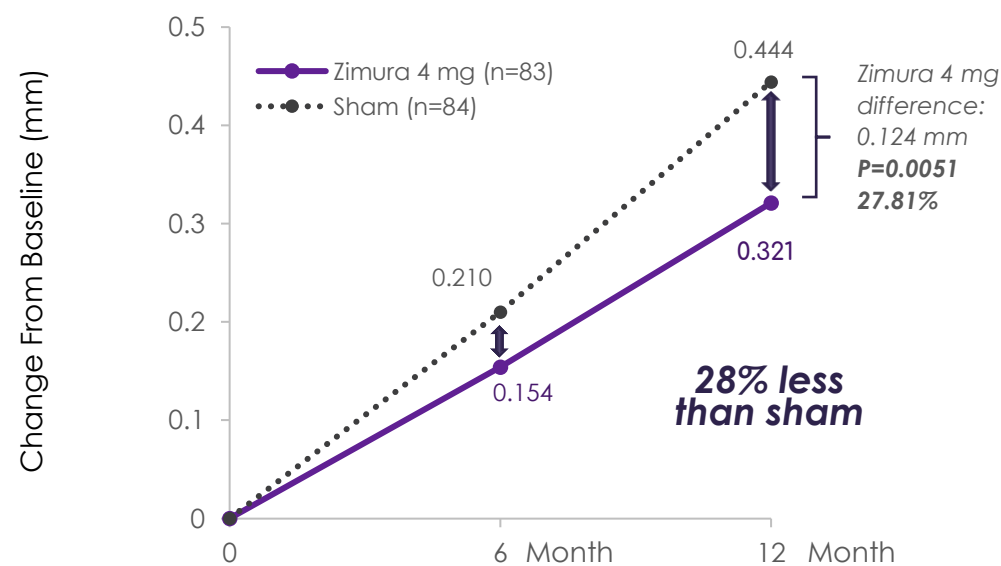
Geographic Atrophy Therapy Trial

MEAN RATE OF GROWTH IN GA AREA AS MEASURED BY SQUARE ROOT TRANSFORMATION OVER 12 MONTHS

Zimura 2 mg vs sham*



Zimura 4 mg vs sham

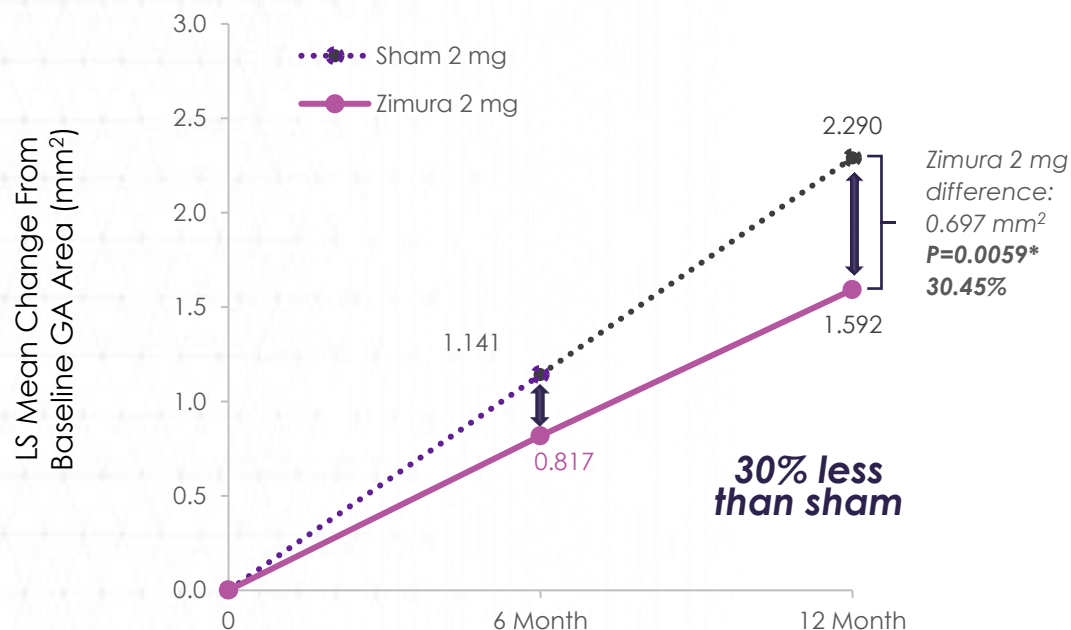


Zimura treatment significantly slowed growth of square-root GA lesion area over 12 months

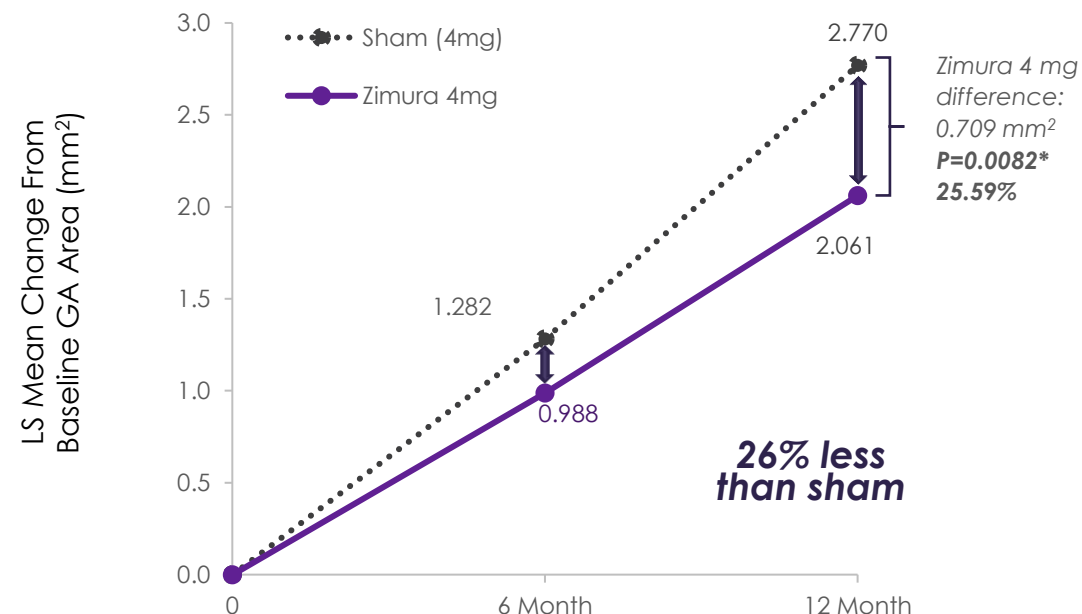
Results remain consistent, irrespective of analysis methodology (non-square-root analysis)

MEAN RATE OF GROWTH IN GA AREA AS MEASURED IN NON-SQUARE-ROOT GA LESION AREA OVER 12 MONTHS

Zimura 2 mg vs sham**



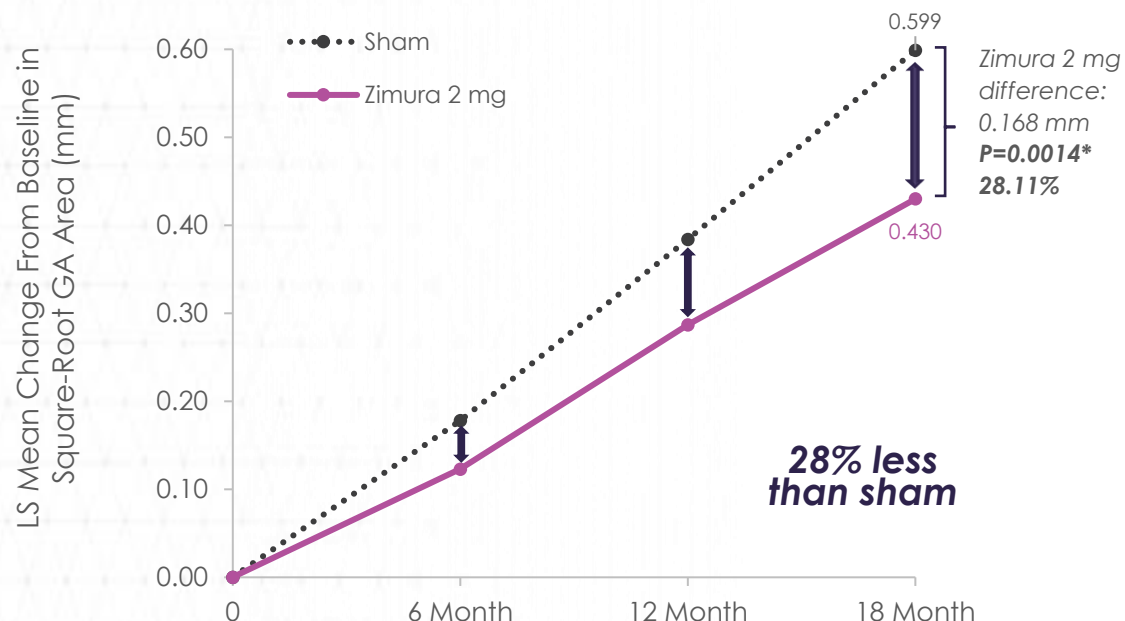
Zimura 4 mg vs sham



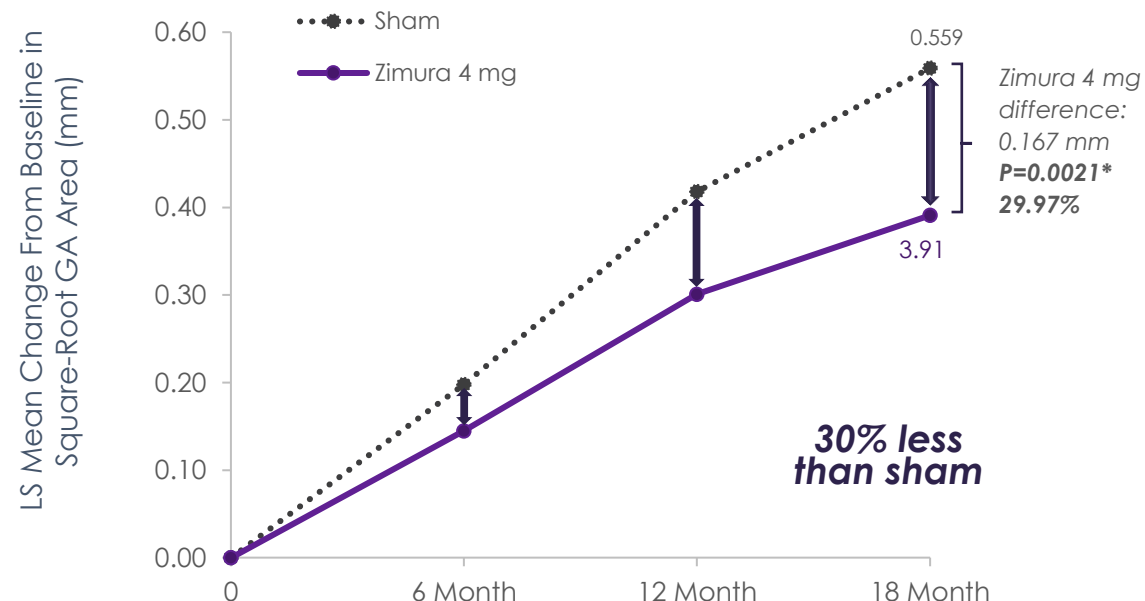
Early & continuous separation through 18 months

MEAN RATE OF GROWTH IN GA AREA AS MEASURED BY SQUARE ROOT TRANSFORMATION OVER 18 MONTHS

Zimura 2 mg vs sham



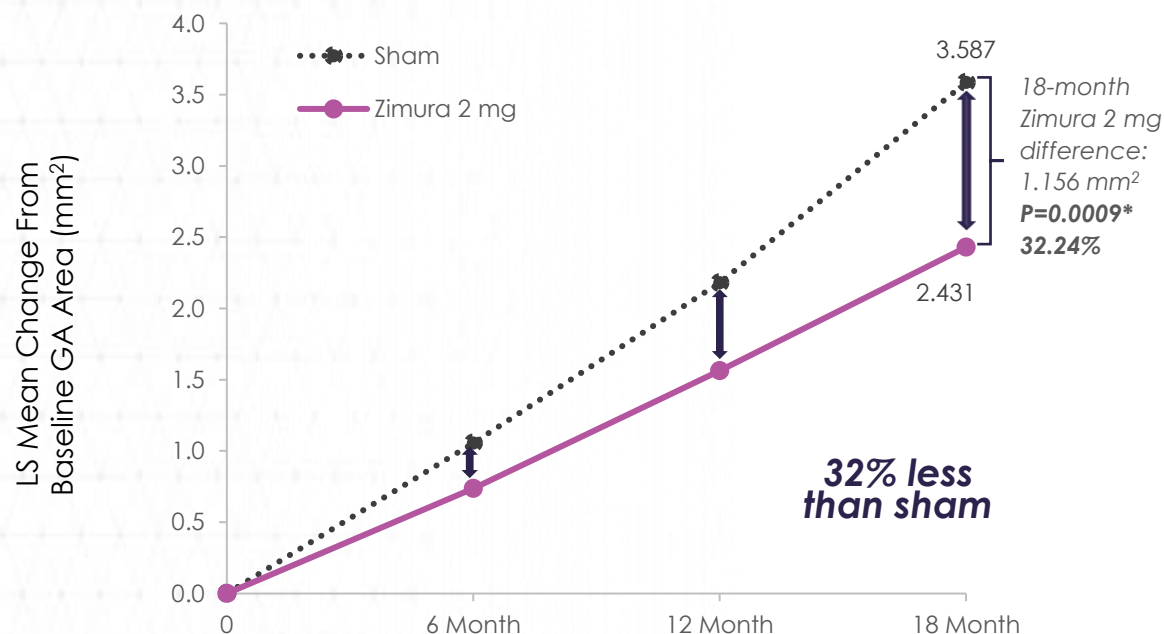
Zimura 4 mg vs sham



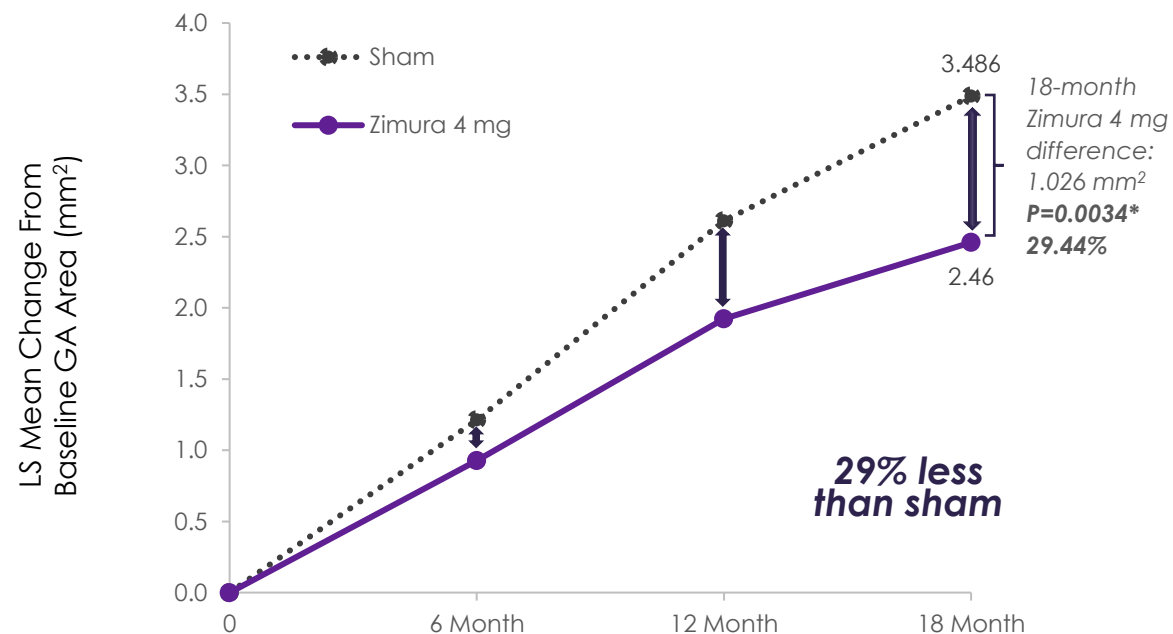
18-month results remain consistent, irrespective of analysis methodology (non-square-root analysis)

MEAN RATE OF GROWTH IN GA AREA AS MEASURED IN NON-SQUARE-ROOT GA LESION AREA OVER 18 MONTHS

Zimura 2 mg vs sham



Zimura 4 mg vs sham



Zimura was generally well tolerated over 18 months



Zimura was well tolerated after 18 months of continuous administration



No reported Zimura-related inflammation



The most frequently reported ocular adverse events were related to the injection procedure*

Incidence of study eye CNV:

n (%)	12 months	18 months
Sham	3 (2.7%)	3 (2.7%)
Zimura 1mg	1 (4.0%)	2 (7.7%)
Zimura 2mg	6 (9.0%)	8 (11.9%)
Zimura 4mg	8 (9.6%)	13 (15.7%)



Key takeaways

- ✓ The prespecified primary efficacy endpoint (reduction in rate of GA growth) was achieved
- ✓ GATHER1 is the only known pivotal trial in GA with results showing continuous treatment effect over 18 months, yielding a ~28% reduction in the rate of GA growth* in the Zimura 2mg group vs sham
- ✓ Zimura was generally well tolerated over 18 months
- ✓ GATHER2, the second pivotal clinical trial in GA, is continuing to enroll patients

IVERIC
BIO

ZIMURA® GATHER2
Geographic Atrophy Therapy Trial

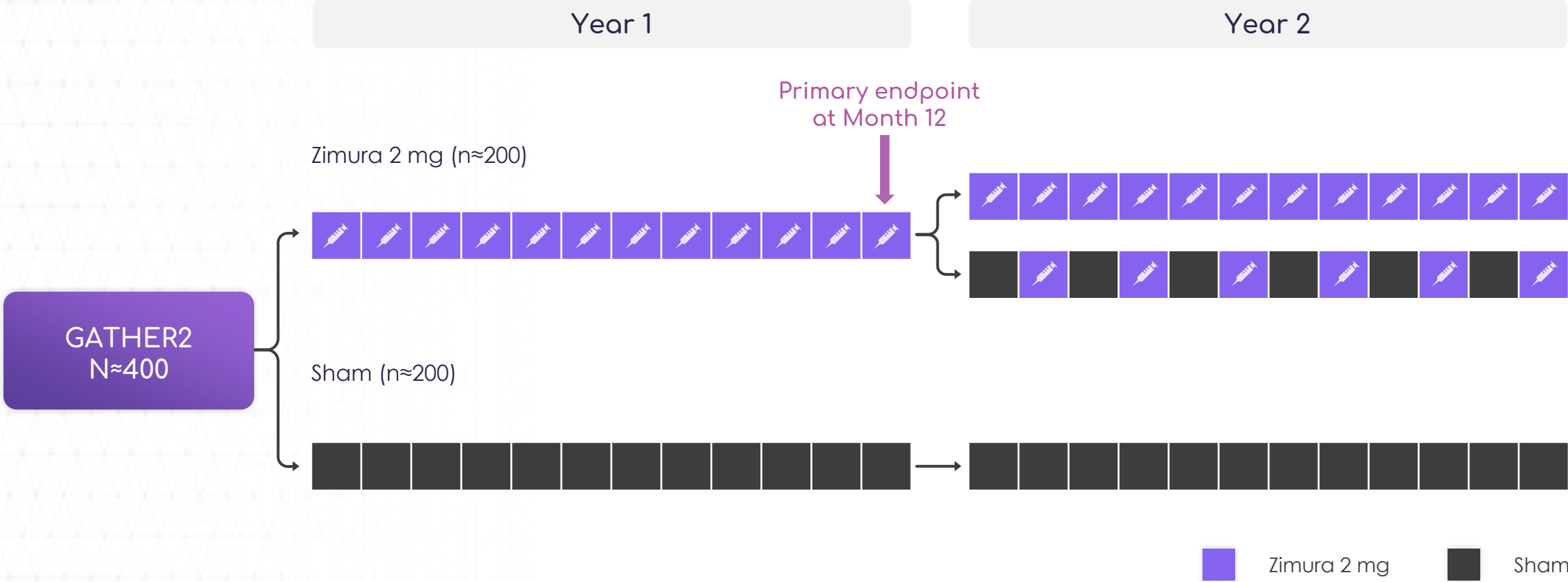
Trial Design and Progress

ARSHAD M. KHANANI, MD, MA

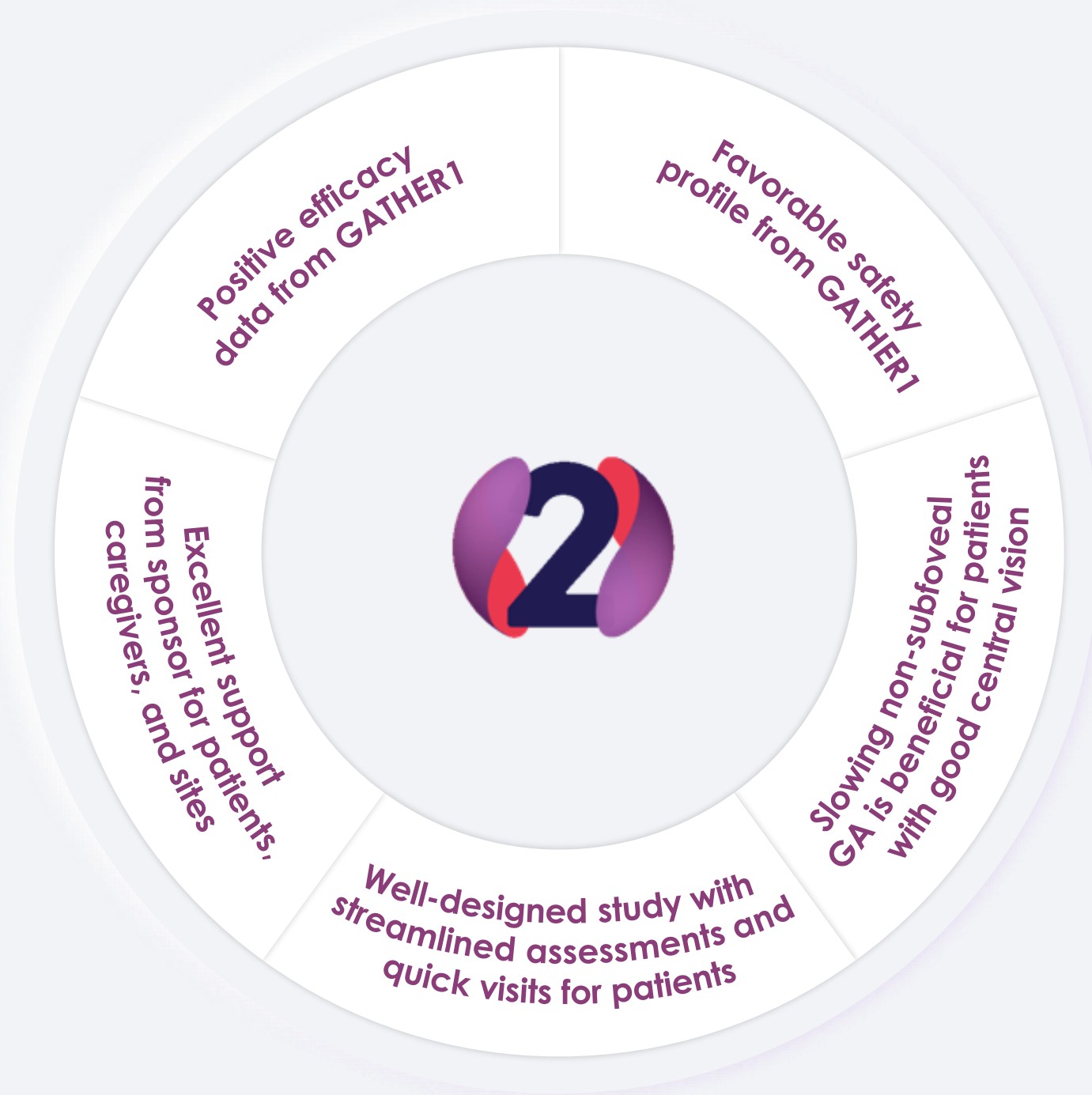Managing Partner and Director of Clinical Research
Sierra Eye Associates, Reno, NV

Chairman, GATHER2 Steering Committee

GATHER2 Primary endpoint at Month 12

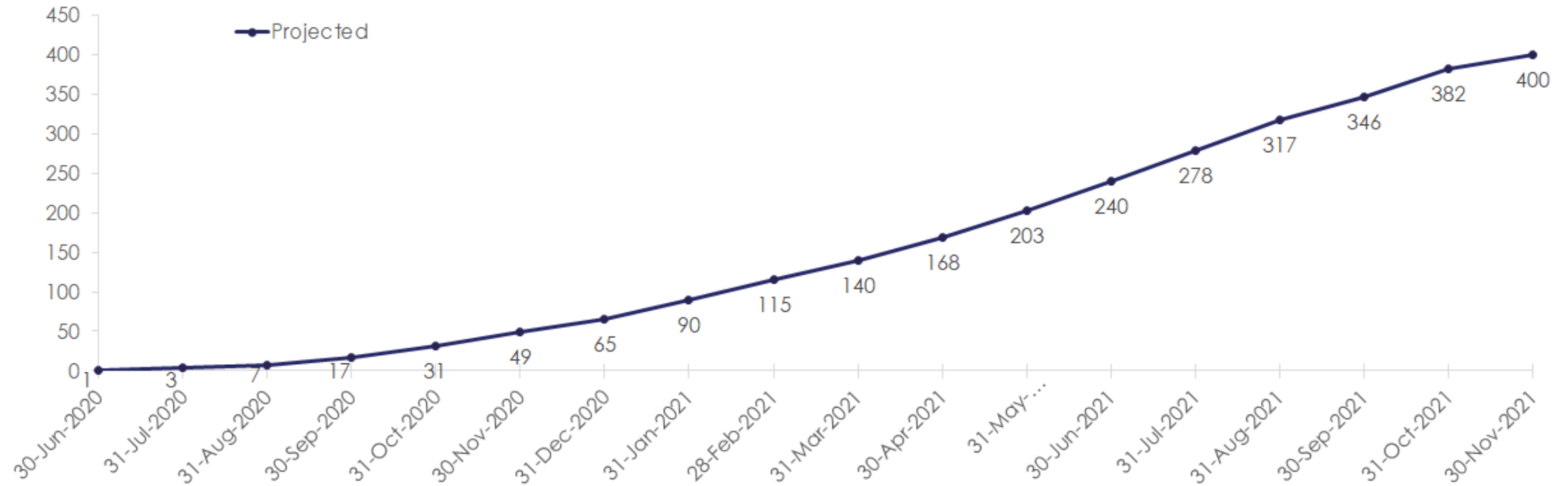


The physician's
perspective: A
preferred study



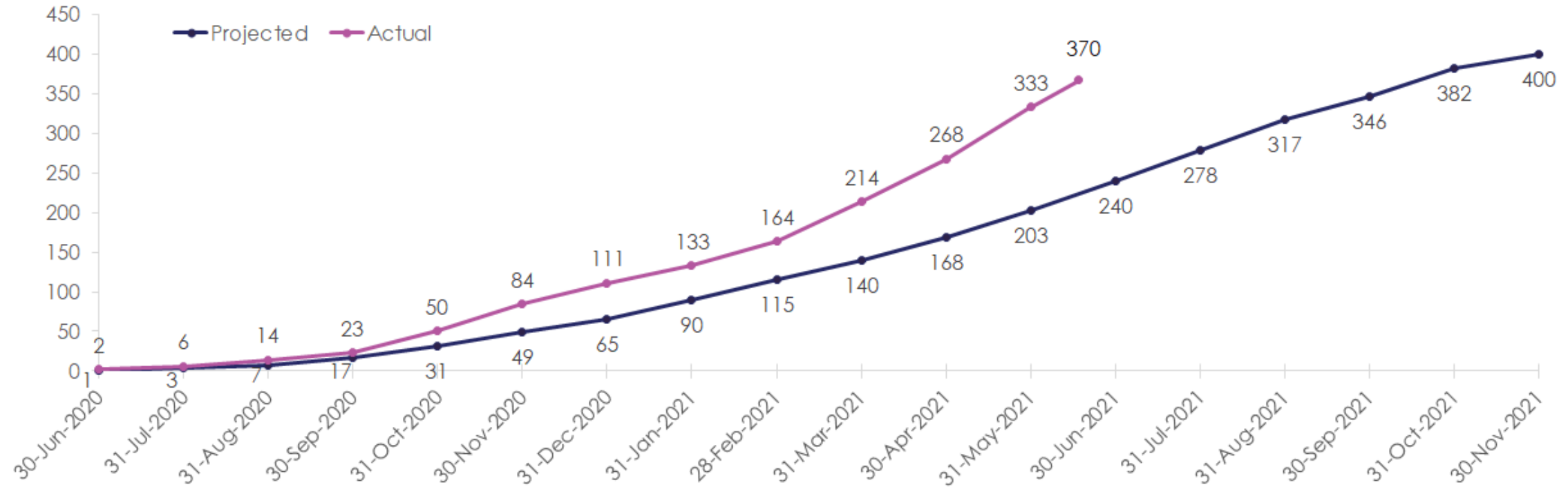
GATHER² Enrollment has remained strong throughout the pandemic

Projected enrollment



GATHER² Enrollment has remained strong throughout the pandemic

Actual vs Projected enrollment



GATHER 2 Patient retention has also remained strong throughout the pandemic

Number of Patients
Currently on Study

362

Number of Patients
Randomized to Date

370

Patient Retention Rate*

97.8%

*As of 6/17/21

Injection fidelity is the most meaningful marker of patient retention

GATHER¹

12-Month Injection Fidelity Rate

87%

Injection Fidelity Calculation:

Total Number of Injections or Sham Administered
÷
Total Randomized Subjects x 12 Injections or Sham

Injection fidelity is the most meaningful marker of patient retention

GATHER 1

12-Month Injection Fidelity Rate

87%

Injection Fidelity Calculation:

Total Number of Injections or Sham Administered
÷
Total Randomized Subjects x 12 Injections or Sham

GATHER 2

Current Injection Fidelity Rate*

> 95%

Injection Fidelity Calculation:

Total Number of Injections or Sham Administered
÷
Total Number of expected injections or Sham
(Based on Current Enrollment*)

*As of 6/17/21

GATHER2

Geographic Atrophy Therapy Trial

TO LEARN MORE, PLEASE VISIT

gather2trial.com

clinicaltrials.gov/ct2/show/NCT04435366



ZIMURA® DEMONSTRATES A REDUCTION IN PROGRESSION OF NASCENT GA AND DRUSEN TO GEOGRAPHIC ATROPHY

Results from a Post-hoc Analysis of GATHER1

VAS R. SADDA, MD

Professor of Ophthalmology
University of California Los Angeles

Earlier endpoints for atrophy associated with AMD

- ✓ If effective treatments for atrophic AMD can be developed, it may be ideal to intervene early, prior to the development of irreversible loss of photoreceptors and vision
- ✓ This requires the development of earlier endpoints to describe the progression of early AMD to atrophy
- ✓ Main rationale for establishment of the Classification of Atrophy/AMD Meetings (CAM) program

CAM program

Assembly of a worldwide (5 continents) group of experts in reading center methods, clinical imaging, AMD histopathology, and imaging technology

- Alan Bird
- Barbara Blodi
- Ferdinando Bottoni
- Usha Chakravarthy
- Emily Chew
- Karl Csaky
- Christine Curcio
- Ronald Danis
- Monika Fleckenstein
- K. Bailey Freund
- Juan Grunwald
- Robyn Guymer
- Carel Hoyng
- Frank Holz
- Glenn Jaffe
- Sandra Liakopoulos
- Jordi Mones
- Daniel Pauleikhoff
- Philip Rosenfeld
- Srinivas Sadda
- David Sarraf
- S. Schmitz-Valckenberg
- Richard Spaide
- Giovanni Staurenghi
- Ramin Tadayoni
- Adnan Tufail
- Sebastian Wolf

Optimal imaging modality for defining AMD/atrophy



Imaging Protocols in Clinical Studies in Advanced Age-Related Macular Degeneration

Recommendations from Classification of Atrophy Consensus Meetings

Frank G. Holz, MD, FEBO,¹ Srinivas R. Sadda, MD,² Giovanni Staurenghi, MD, FARVO,³ Moritz Lindner, MD,¹ Alan C. Bird, MD, FARVO,⁴ Barbara A. Blodi, MD,⁵ Ferdinando Bottoni, MD, FEBO,³ Usha Chakravarthy, MBBS, PhD,⁶ Emily Y. Chew, MD, FARVO,⁷ Karl Csaky, MD, PhD,⁸ Christine A. Curcio, PhD, FARVO,⁹ Ron Danis, MD,⁷ Monika Fleckenstein, MD,¹ K. Bailey Freund, MD,¹⁰ Juan Granwald, MD,¹¹ Robyn Guymer, MBBS, PhD,¹² Carel B. Hoyng, MD, PhD,¹³ Glenn J. Jaffe, MD, FARVO,¹⁴ Sandra Liakopoulos, MD,¹⁵ Jordi M. Monés, MD, PhD,¹⁶ Akio Oishi, MD, PhD,¹ Daniel Pauleikhoff, MD,¹⁷ Philip J. Rosenfeld, MD, PhD,¹⁸ David Sarraf, MD,¹⁹ Richard F. Spaide, MD,¹⁰ Ramin Tadayoni, MD, PhD,²⁰ Adnan Tufail, MD, FRCOphth,²¹ Sebastian Wolf, MD, PhD,²² Steffen Schmitz-Valckenberg, MD, FEBO,¹ on behalf of the CAM group*

Purpose: To summarize the results of 2 consensus meetings (Classification of Atrophy Meeting [CAM]) on conventional and advanced imaging modalities used to detect and quantify atrophy due to late-stage non-neovascular and neovascular age-related macular degeneration (AMD) and to provide recommendations on the use of these modalities in natural history studies and interventional clinical trials.

Design: Systematic debate on the relevance of distinct imaging modalities held in 2 consensus meetings.

Participants: A panel of retina specialists.

Methods: During the CAM, a consortium of international experts evaluated the advantages and disadvantages of various imaging modalities on the basis of the collective analysis of a large series of clinical cases. A systematic discussion on the role of each modality in future studies in non-neovascular and neovascular AMD was held.

Main Outcome Measures: Advantages and disadvantages of current retinal imaging technologies and recommendations for their use in advanced AMD trials.

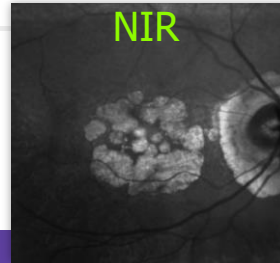
Results: Imaging protocols to detect, quantify, and monitor progression of atrophy should include color fundus photography (CFP), confocal fundus autofluorescence (FAF), confocal near-infrared reflectance (NIR), and high-resolution optical coherence tomography volume scans. These images should be acquired at regular intervals throughout the study. In studies of non-neovascular AMD (without evident signs of active or regressed neovascularization [NV] at baseline), CFP may be sufficient at baseline and end-of-study visit. Fluorescein angiography (FA) may become necessary to evaluate for NV at any visit during the study. Indocyanine-green angiography (ICG-A) may be considered at baseline under certain conditions. For studies in patients with neovascular AMD, increased need for visualization of the vasculature must be taken into account. Accordingly, these studies should include FA (recommended at baseline and selected follow-up visits) and ICG-A under certain conditions.

Conclusions: A multimodal imaging approach is recommended in clinical studies for the optimal detection and measurement of atrophy and its associated features. Specific validation studies will be necessary to determine the best combination of imaging modalities, and these recommendations will need to be updated as new imaging technologies become available in the future. *Ophthalmology* 2016;125:1–15 © 2016 by the American Academy of Ophthalmology

*Supplemental material is available at www.aaojournal.org.

In industrialized countries, late-stage age-related macular degeneration (AMD) is the leading cause of legal blindness in the elderly.^{1,2} It presents with neovascularization (NV) or geographic atrophy (GA).³ Both manifestations are not

mutually exclusive; atrophy develops in eyes with NV effectively treated with intravitreal anti-vascular endothelial growth factor (VEGF) injections both within and outside the area of NV.^{4–7} In eyes developing atrophy without

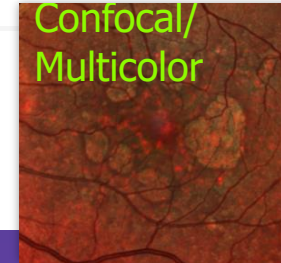


Advantages

- Resistant to media opacities
- Auxiliary for foveal assessment
- Enables detection of reticular pseudodrusen and atrophy
- Build-in in most OCT/SLO devices

Disadvantages

- Lack of validation studies for late-stage AMD
- Findings are of yet unstudied specificity
- Cannot be used as stand-alone technology

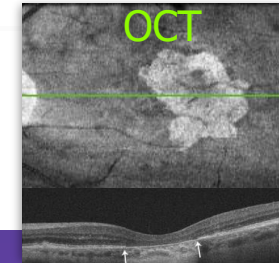


Advantages

- High precision and contrast
- Displays many, but not all findings from CFP
- Hyper-pigmentation difficult to distinguish from hemorrhage
- Contrast between atrophy and fibrosis
- Detection of pseudodrusen

Disadvantages

- No true-color image
- Mainly carrying the information from NIR
- Limited evidence from validation studies
- Limited availability



Advantages

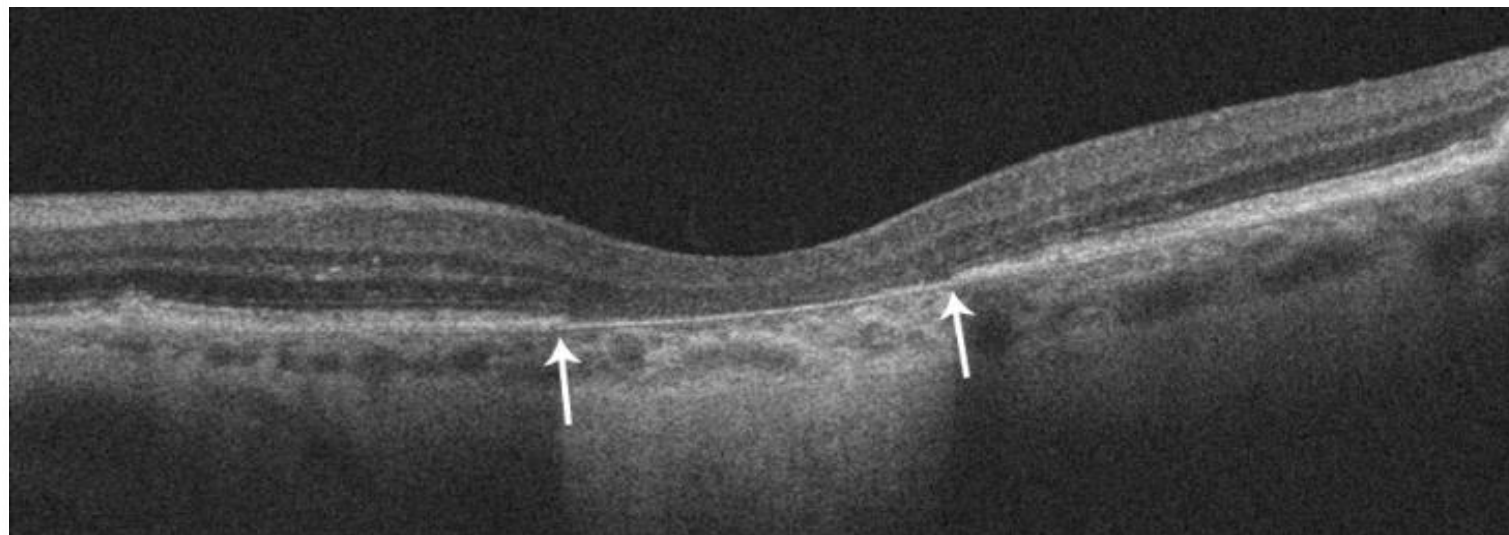
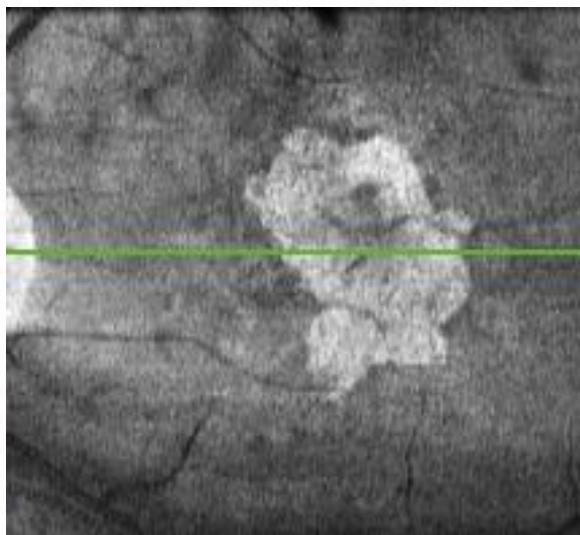
- Broadly available
- Cross-sectional morphology of retina, RPE and choroid
- Correlated with histology
- Validated to assess RPE atrophy progression and neovascular changes
- Anatomical tracking functions for exact re-positioning of follow-up scans
- Advances in lateral resolution and scanning speed expected in near future
- Identification of pre-atrophic features
- Comfortable for patients

Disadvantages

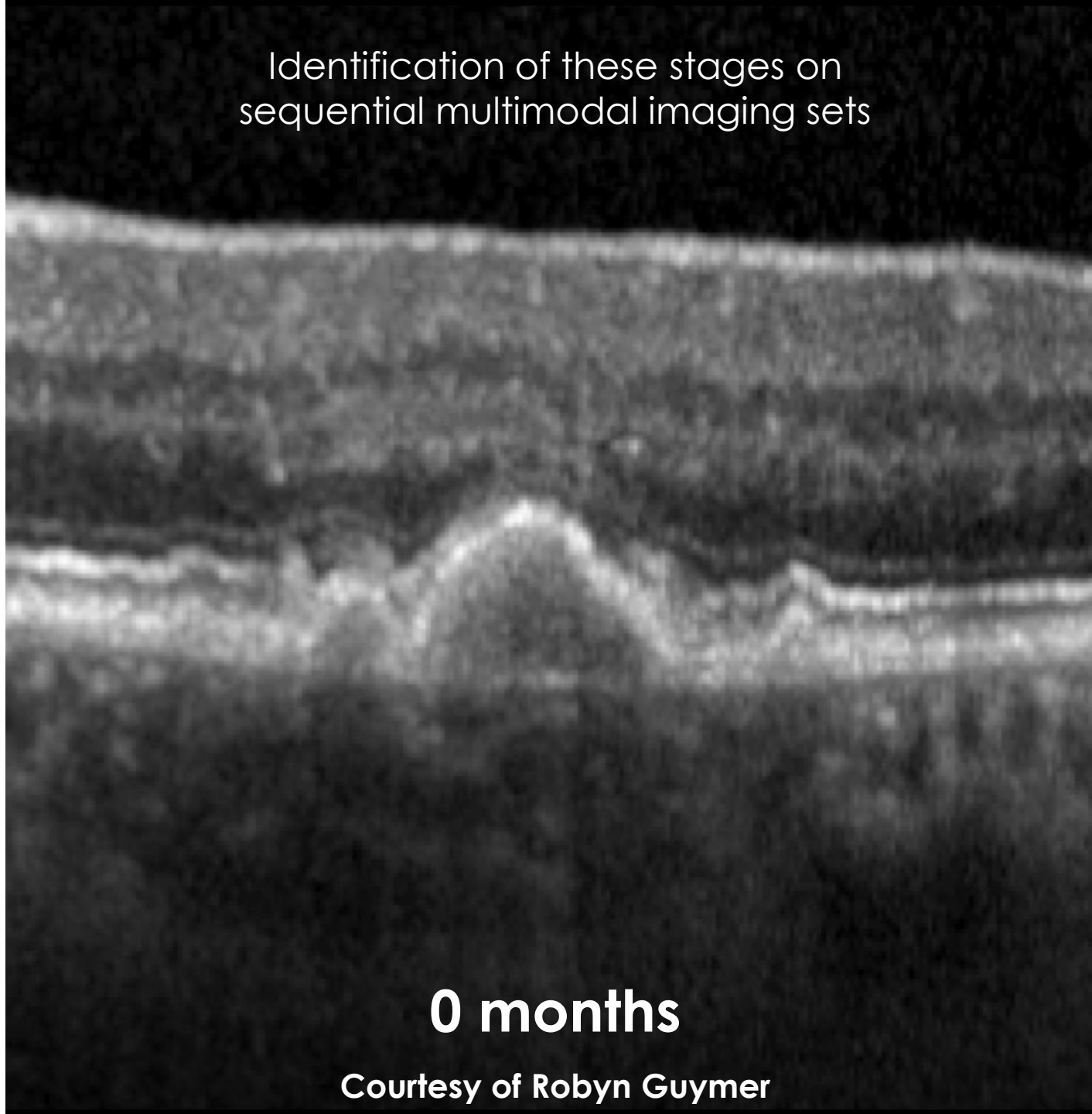
- Scan field limited
- Interpretation strongly dependent on imaging quality
- Lack of industry standards
- 3D datasets require sophisticated analysis software and longer reading times for detailed slab analyses of retinal and choroidal layers
- Automated segmentation imperfection and instrument dependent
- Definition of atrophy border and relevance of certain prognostic biomarkers still controversial

Optimal imaging modality for defining AMD/Atrophy

OCT established to be the optimal reference modality to allow study of AMD progression and early endpoint development as it allowed specific layers (photoreceptors, RPE) to be evaluated



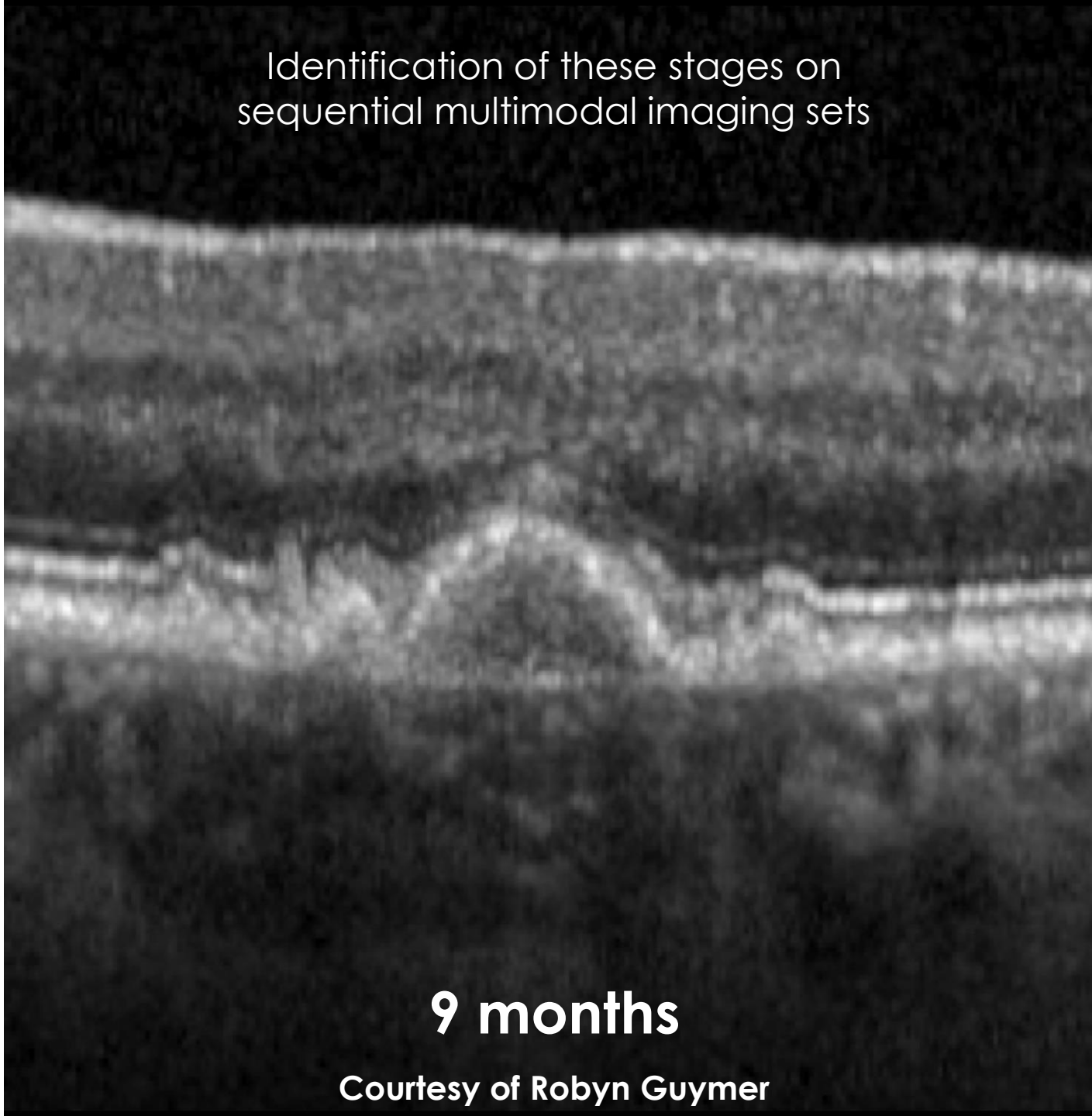
Identification of these stages on
sequential multimodal imaging sets



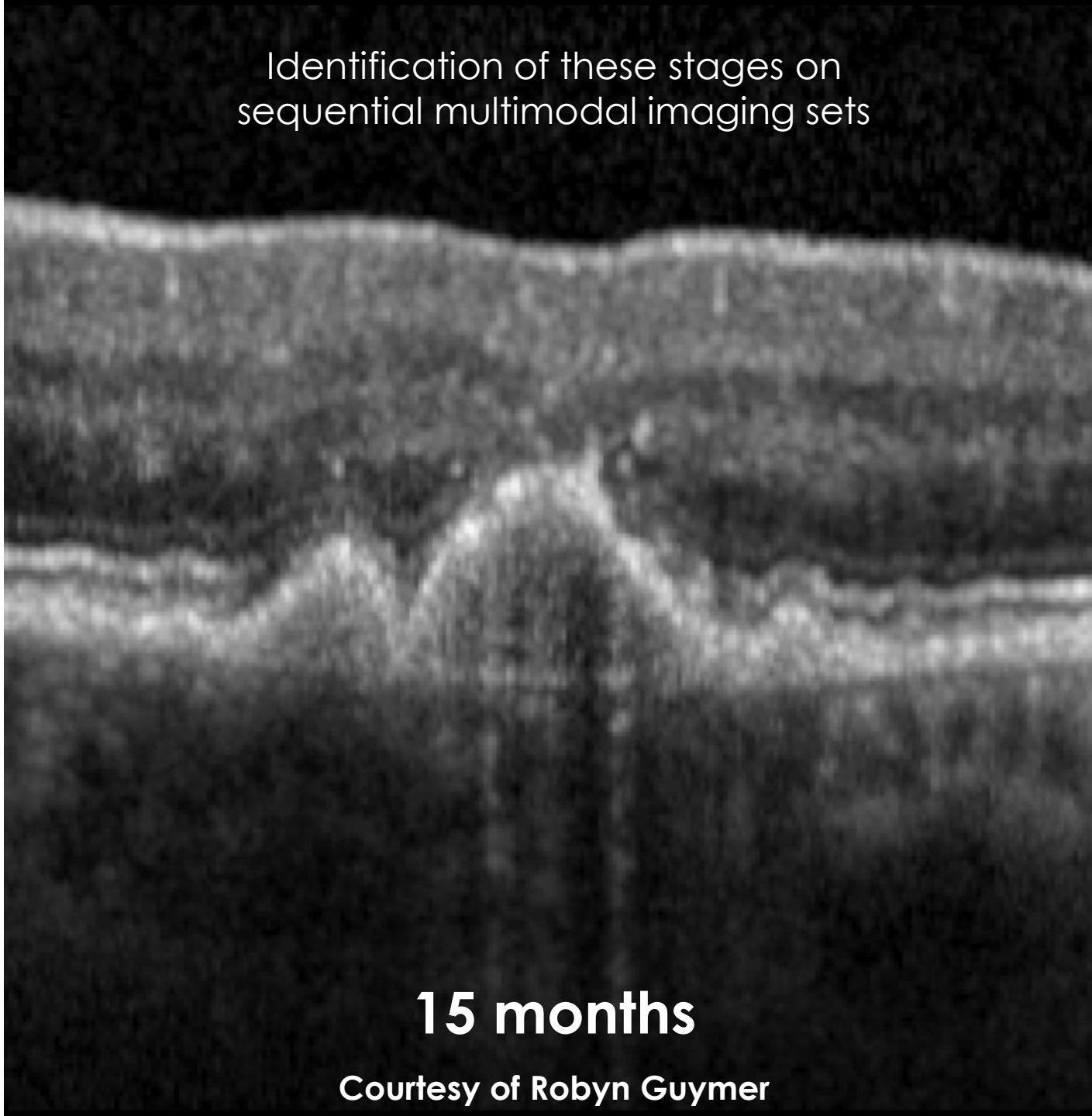
0 months

Courtesy of Robyn Guymer

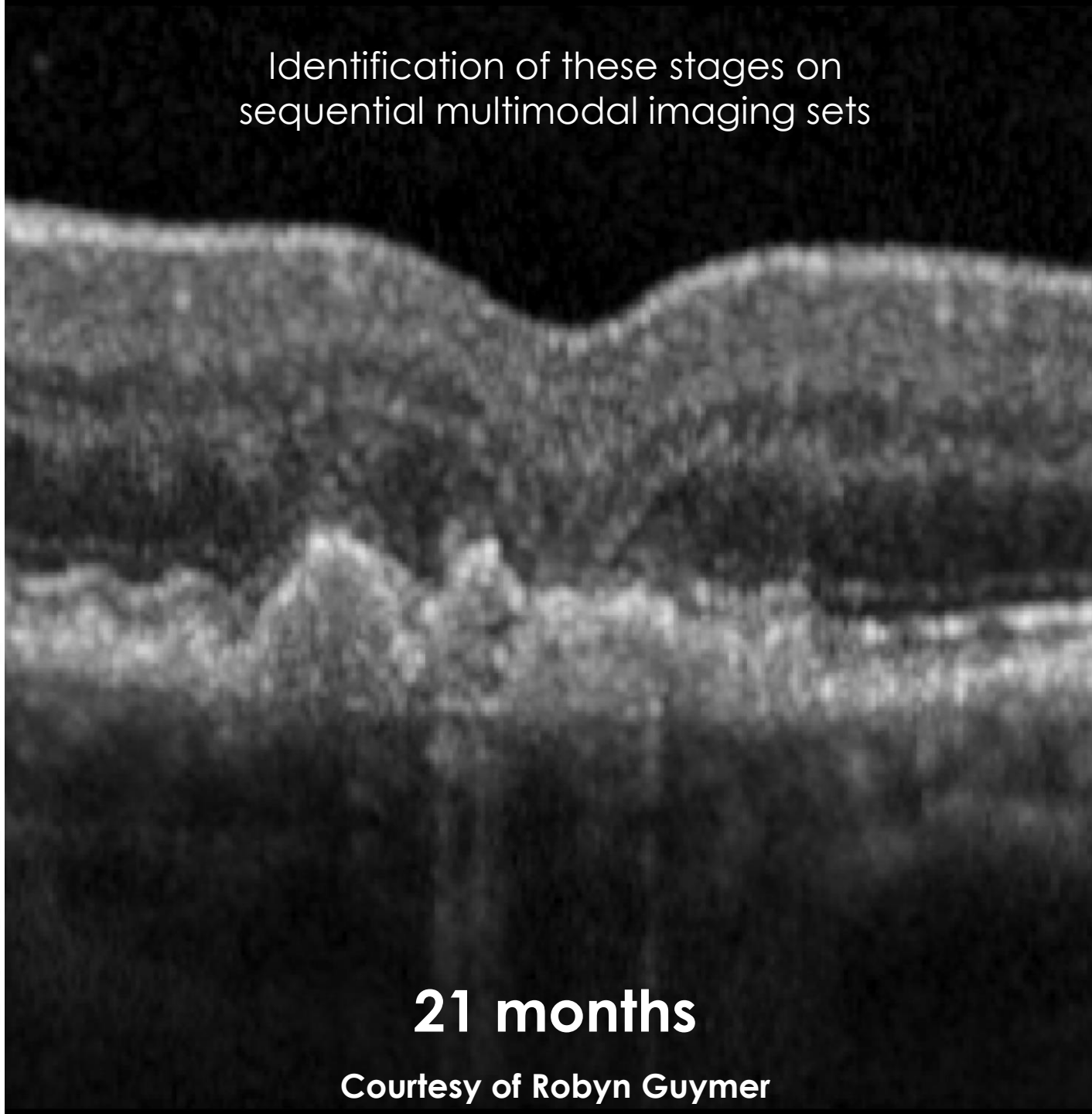
Identification of these stages on
sequential multimodal imaging sets



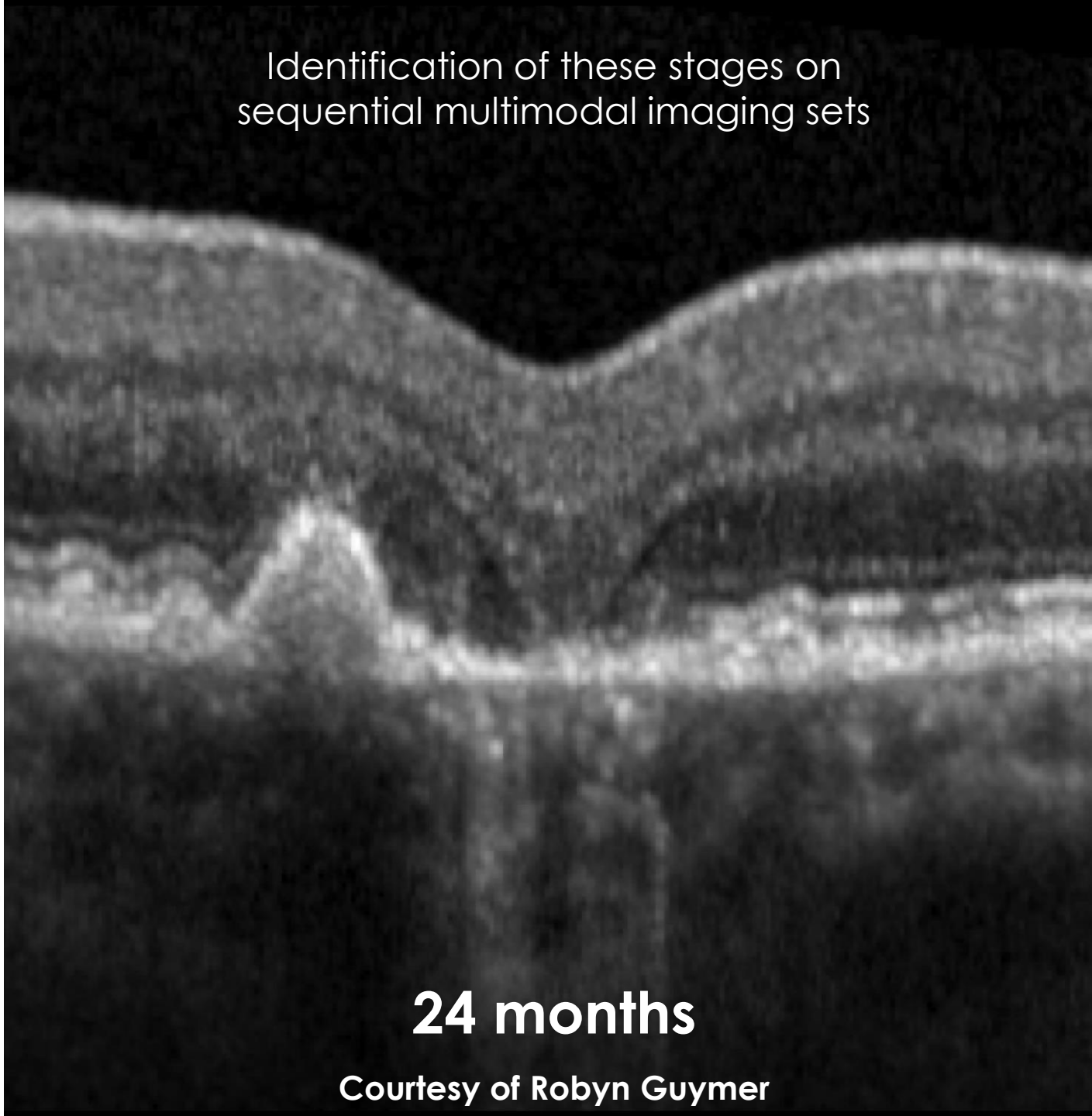
Identification of these stages on
sequential multimodal imaging sets



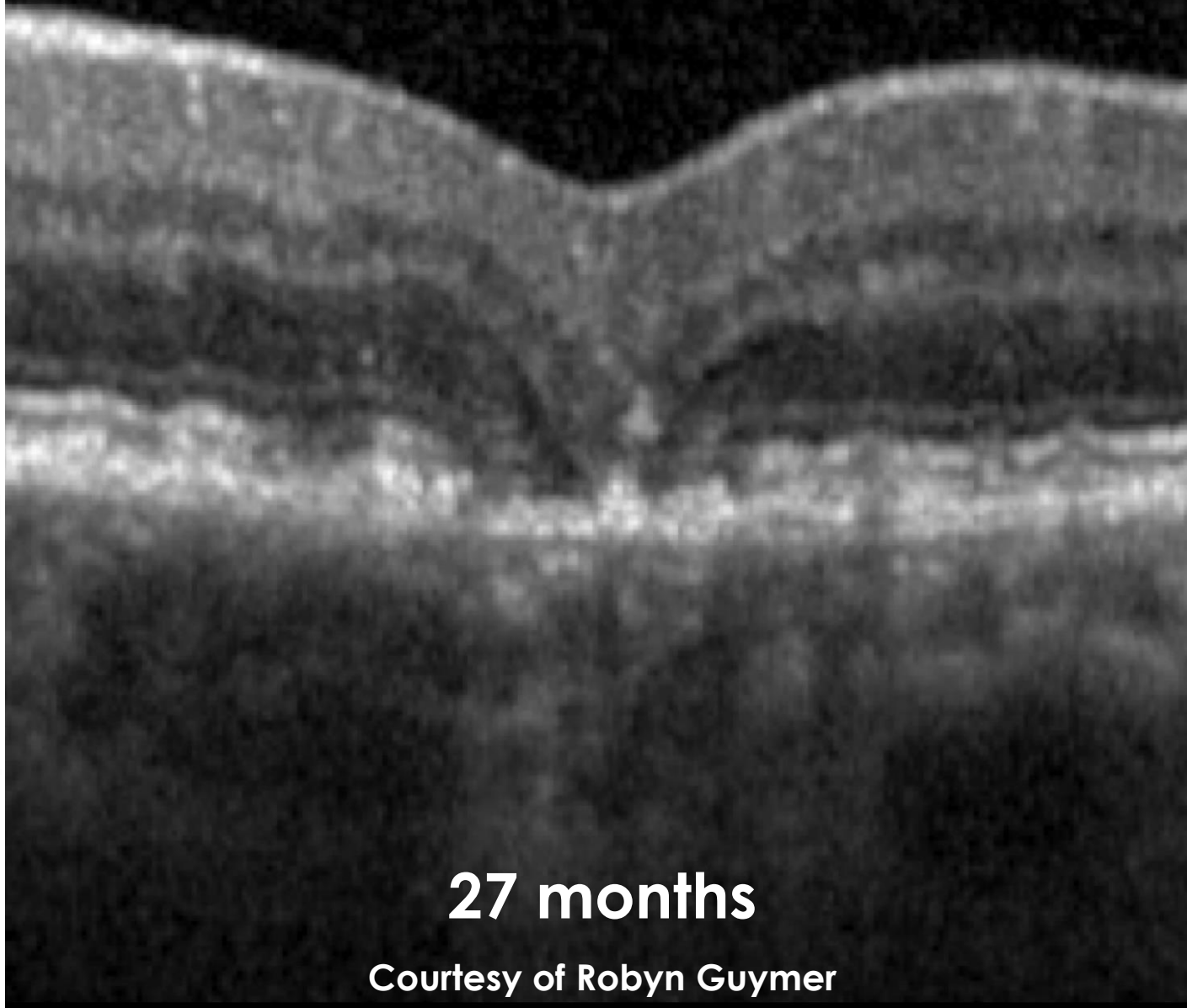
Identification of these stages on
sequential multimodal imaging sets



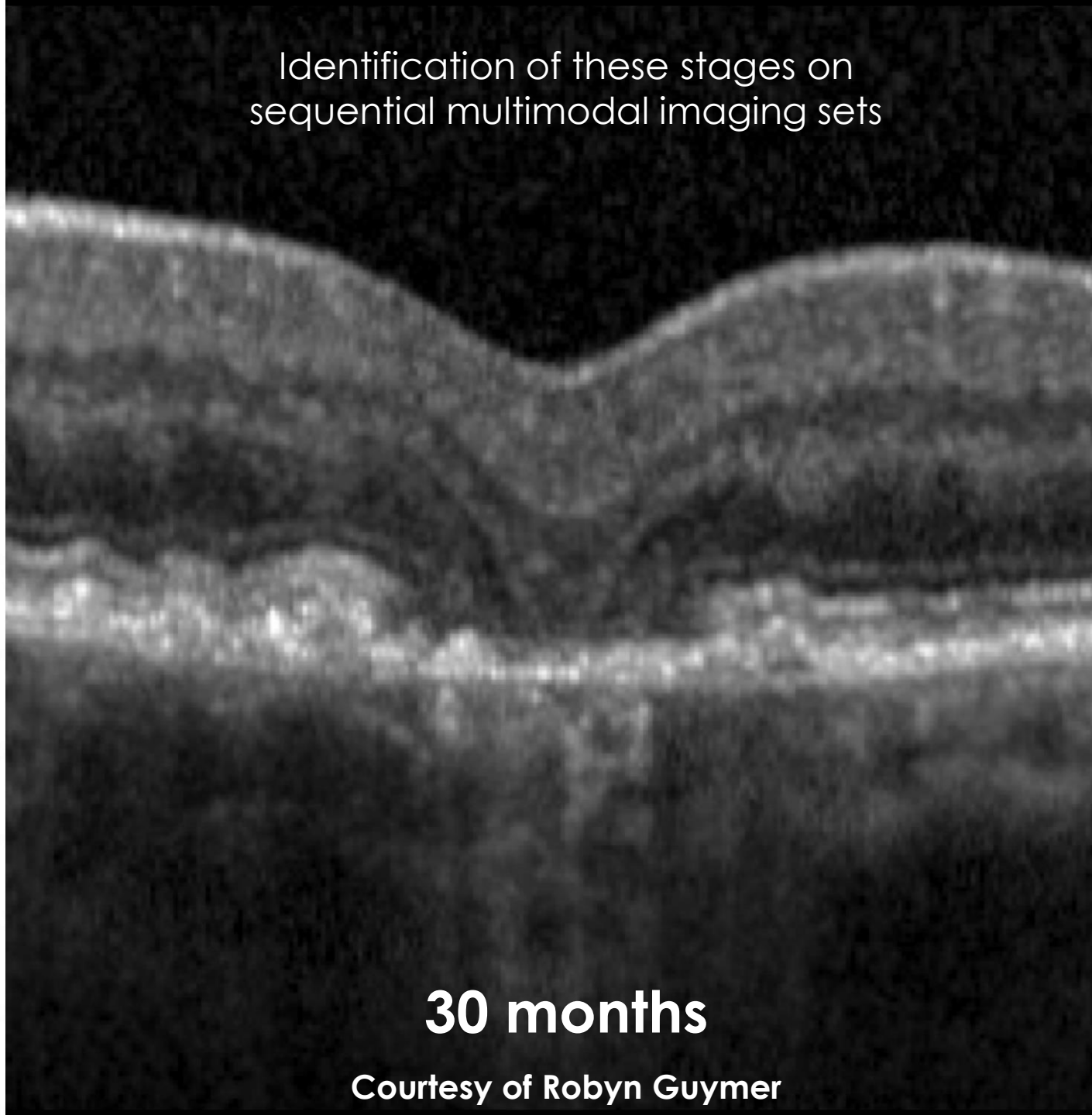
Identification of these stages on
sequential multimodal imaging sets



Identification of these stages on
sequential multimodal imaging sets



Identification of these stages on
sequential multimodal imaging sets

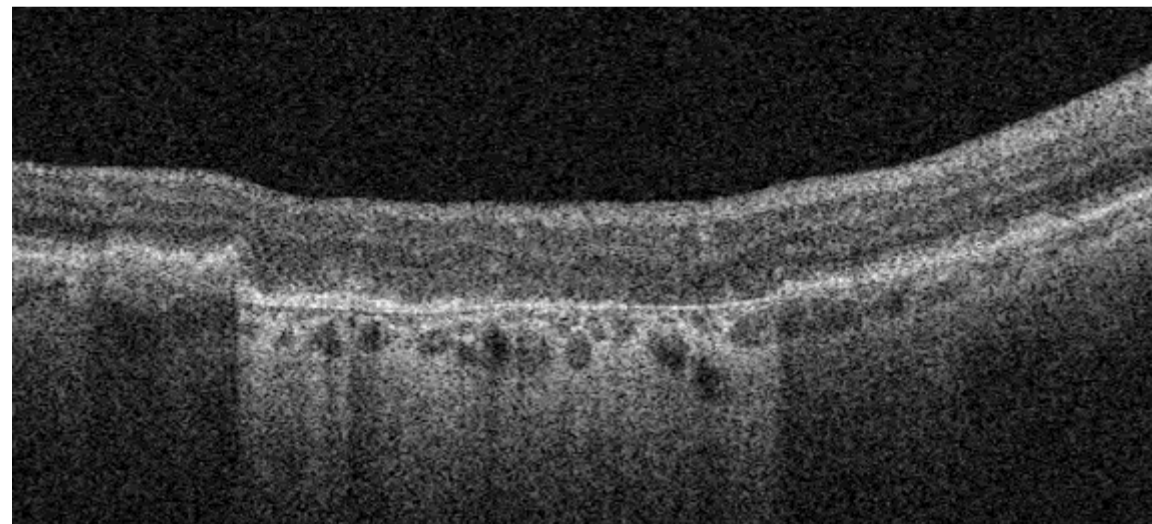


CAM consensus definitions for atrophic lesions

Complete RPE + Outer Retinal Atrophy
(cRORA)

GA is a subset of cRORA
(excludes region of CNV)

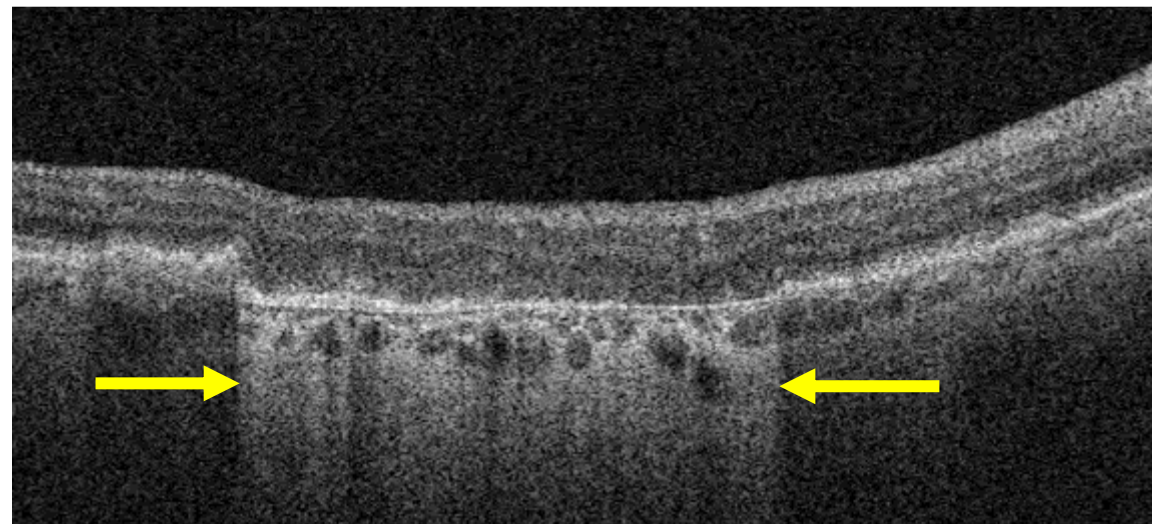
Must have all 3 of the following:



CAM consensus definitions for atrophic lesions

Complete RPE + Outer Retinal Atrophy
(cRORA)

GA is a subset of cRORA
(excludes region of CNV)



Must have all 3 of the following:

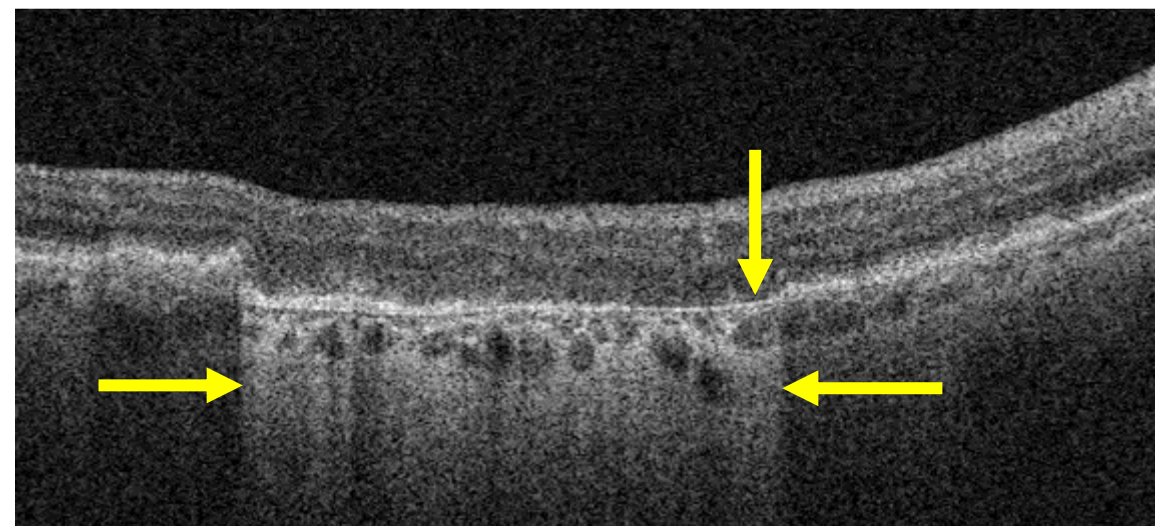
1

Hypertransmission of
≥250 micrometers

CAM consensus definitions for atrophic lesions

Complete RPE + Outer Retinal Atrophy
(cRORA)

GA is a subset of cRORA
(excludes region of CNV)



Must have all 3 of the following:

1

Hypertransmission of
 ≥ 250 micrometers

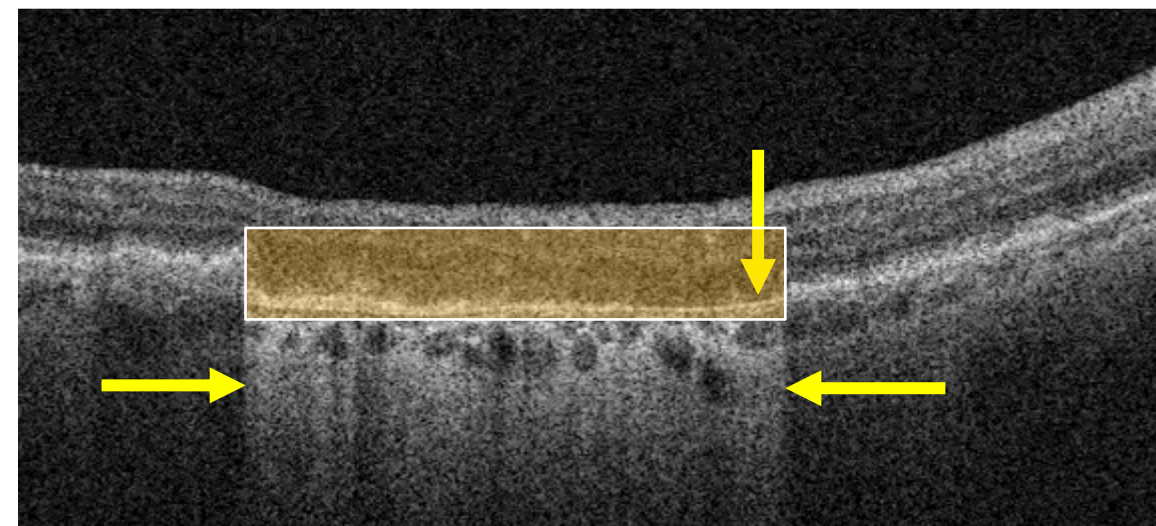
2

Zone of attenuation
/disruption of RPE+/-BL
complex of ≥ 250 micrometers

CAM consensus definitions for atrophic lesions

Complete RPE + Outer Retinal Atrophy
(cRORA)

GA is a subset of cRORA
(excludes region of CNV)



Must have all 3 of the following:

1

Hypertransmission of
 ≥ 250 micrometers

2

Zone of attenuation
/disruption of RPE+/-BL
complex of ≥ 250 micrometers

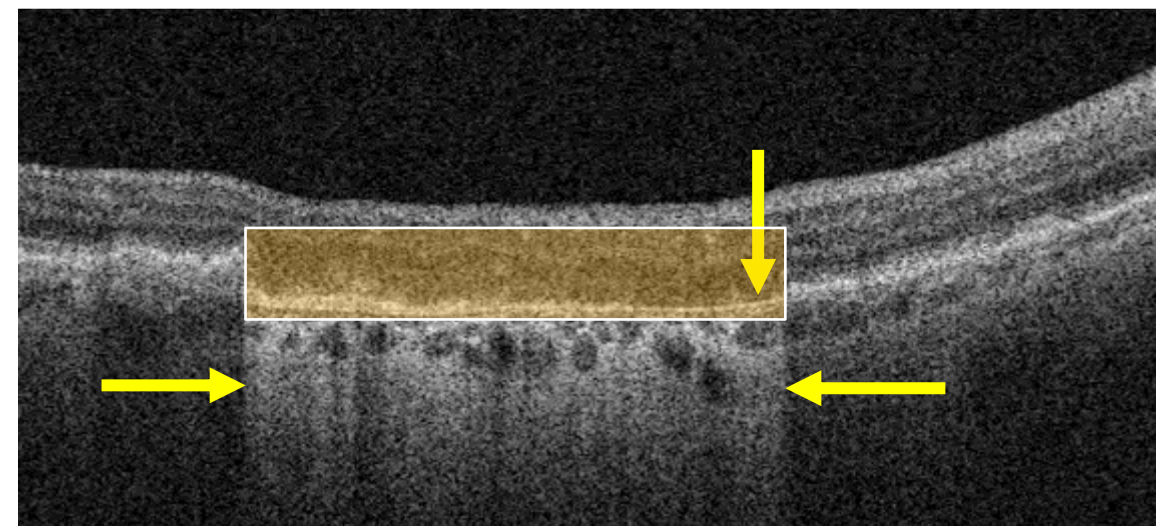
3

Evidence of overlying
photoreceptor degeneration
whose features include ONL
thinning, ELM loss, and EZ/IZ loss

CAM consensus definitions for atrophic lesions

Complete RPE + Outer Retinal Atrophy
(cRORA)

GA is a subset of cRORA
(excludes region of CNV)



Must have all 3 of the following:

1

Hypertransmission of
 ≥ 250 micrometers

2

Zone of attenuation
/disruption of RPE+/-BL
complex of ≥ 250 micrometers

3

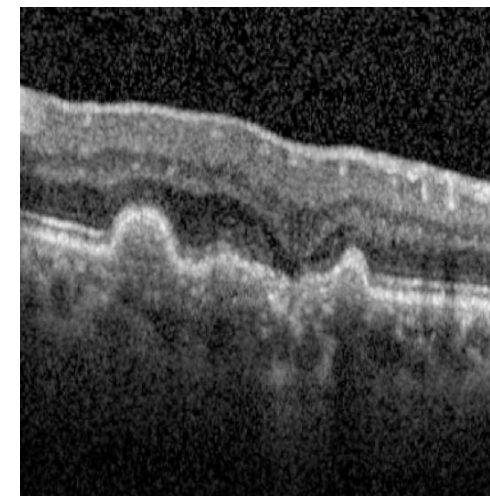
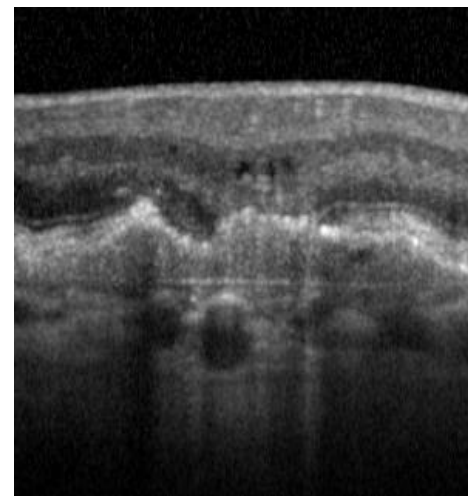
Evidence of overlying
photoreceptor degeneration
whose features include ONL
thinning, ELM loss, and EZ/IZ loss

Cannot Have: Scrolled RPE or other signs of Rip

CAM consensus definitions for atrophic lesions

Incomplete RPE + Outer Retinal Atrophy
(iRORA)

Nascent GA is a subset of iRORA
(excludes region of CNV)



Must have all 3 of the following:

1

Some hypertransmission must be present, but it is often discontinuous

2

Some irregularity of RPE+/-BL complex

3

Detectable photoreceptor degeneration, signs of which can include “wedge” and “subsidence”

Cannot fulfill all criteria for cRORA

Histologic correlation of atrophic lesions

ARTICLE IN PRESS



AMERICAN ACADEMY
OF OPHTHALMOLOGY

Consensus Definition for Atrophy Associated with Age-Related Macular Degeneration on OCT

Classification of Atrophy Report 3

Srinivas R. Sadda, MD,¹ Robyn Gruymer, MBBS, PhD,² Frank G. Holz, MD,³ Steffen Schmitz-Valckenberg, MD,³ Christine A. Curcio, PhD,⁴ Alan C. Bird, MD,⁵ Barbara A. Blodi, MD,⁶ Ferdinando Bottoni, MD,⁷ FEBO,⁸ Usha Chakravarthy, MD, PhD,⁹ Emily Y. Chew, MD,¹⁰ Karl Csaky, MD,¹¹ Ronald P. Danis, MD,¹² Monika Fleckenstein, MD,¹³ K. Bailey Freund, MD,¹⁴ Juan Granwald, MD,¹⁵ Carol B. Hoyng, MD, PhD,¹⁶ Glenn J. Jaffe, MD,¹⁷ Sandra Liskopoulou, MD,¹⁸ Jordi M. Monés, MD, PhD,¹⁹ Daniel Pauleikhoff, MD,¹⁷ Philip J. Rosenfeld, MD, PhD,¹⁸ David Sarraf, MD,¹⁹ Richard F. Spaide, MD,¹⁰ Ramin Tadayoni, MD, PhD,²⁰ Adnan Tufail, MD, FRCOphth,²¹ Sebastian Wolf, MD, PhD,²² Giovanni Staurenghi, MD, FARVO²³

Purpose: To develop consensus terminology and criteria for defining atrophy based on OCT findings in the setting of age-related macular degeneration (AMD).

Design: Consensus meeting.

Participants: Panel of retina specialists, image reading center experts, retinal histologists, and optics engineers.

Methods: As part of the Classification of Atrophy Meetings (GAM) program, an international group of experts surveyed the existing literature, performed a masked analysis of longitudinal multimodal imaging for a series of eyes with AMD, and reviewed the results of this analysis to define areas of agreement and disagreement. Through consensus discussions at 3 meetings over 12 months, a classification system based on OCT was proposed for atrophy secondary to AMD. Specific criteria were defined to establish the presence of atrophy.

Main Outcome Measures: A consensus classification system for atrophy and OCT-based criteria to identify atrophy.

Results: OCT was proposed as the reference standard or base imaging method to diagnose and stage atrophy. Other methods, including fundus autofluorescence, near-infrared reflectance, and color imaging, provided complementary and confirmatory information. Recognizing that photoreceptor atrophy can occur without retinal pigment epithelium (RPE) atrophy and that atrophy can undergo an evolution of different stages, 4 terms and histologic candidates were proposed: complete RPE and outer retinal atrophy (cRORA), incomplete RPE and outer retinal atrophy, complete outer retinal atrophy, and incomplete outer retinal atrophy. Specific OCT criteria to diagnose cRORA were proposed: (1) a region of hypertransmission of at least 250 μ m in diameter, (2) a zone of attenuation or disruption of the RPE of at least 250 μ m in diameter, (3) evidence of overlying photoreceptor degeneration, and (4) absence of scrolled RPE or other signs of an RPE tear.

Conclusions: A classification system and criteria for OCT-defined atrophy in the setting of AMD has been proposed based on an international consensus. This classification is a more complete representation of changes that occur in AMD than can be detected using color fundus photography alone. Longitudinal information is required to validate the implied risk of vision loss associated with these terms. This system will enable such future studies to be undertaken using consistent definitions. *Ophthalmology* 2017;126:1–12 © 2017 by the American Academy of Ophthalmology



Supplemental material available at www.aaojournal.org.

Geographic atrophy (GA) is a well-established end-stage manifestation of age-related macular degeneration (AMD).^{1,2} Gass³ originally described “geographic areas of atrophy” in the context of “senile macular choroidal degeneration” in 1970.⁴ As early as the 19th century, various other terms

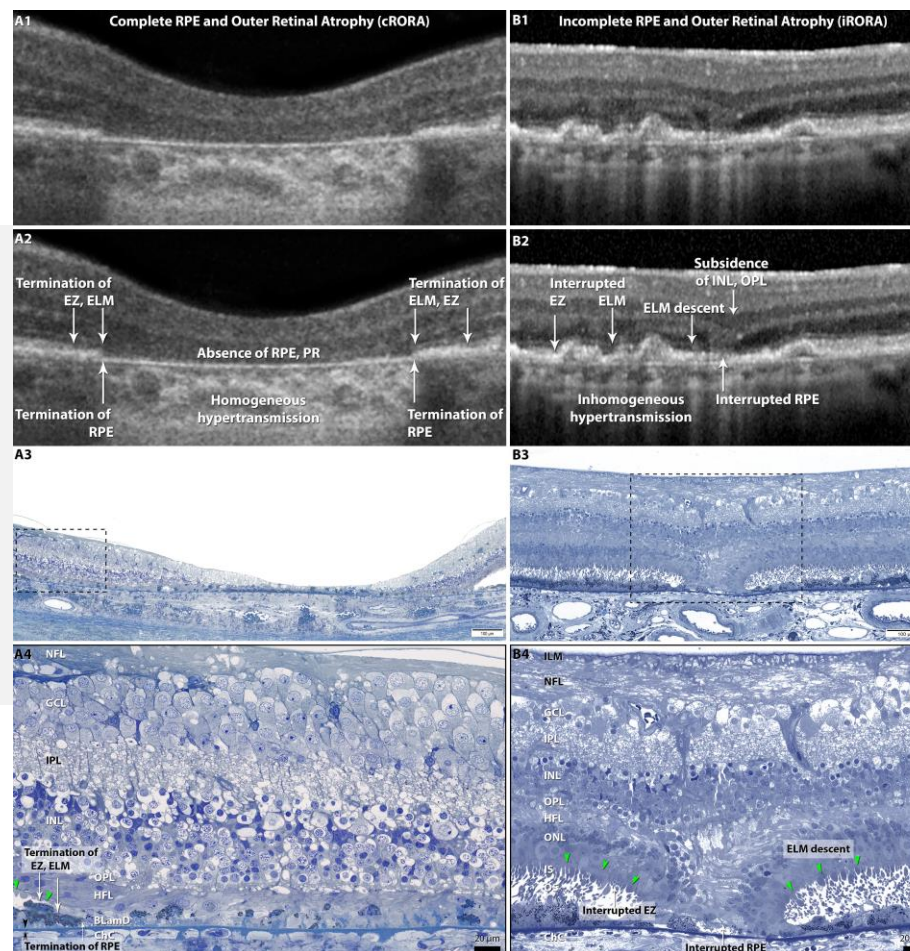
were used in the literature, including *macular heredodegeneration*, *choroidal sclerosis*, and *senile macular disease*. These terms were applied to inflammatory as well as monogenic conditions such as Stargardt disease or central areolar choroidal dystrophy.^{5–8} With the

cRORA

complete

RPE and Outer Retinal Atrophy

(GA is a subset in absence of CNV)



iRORA

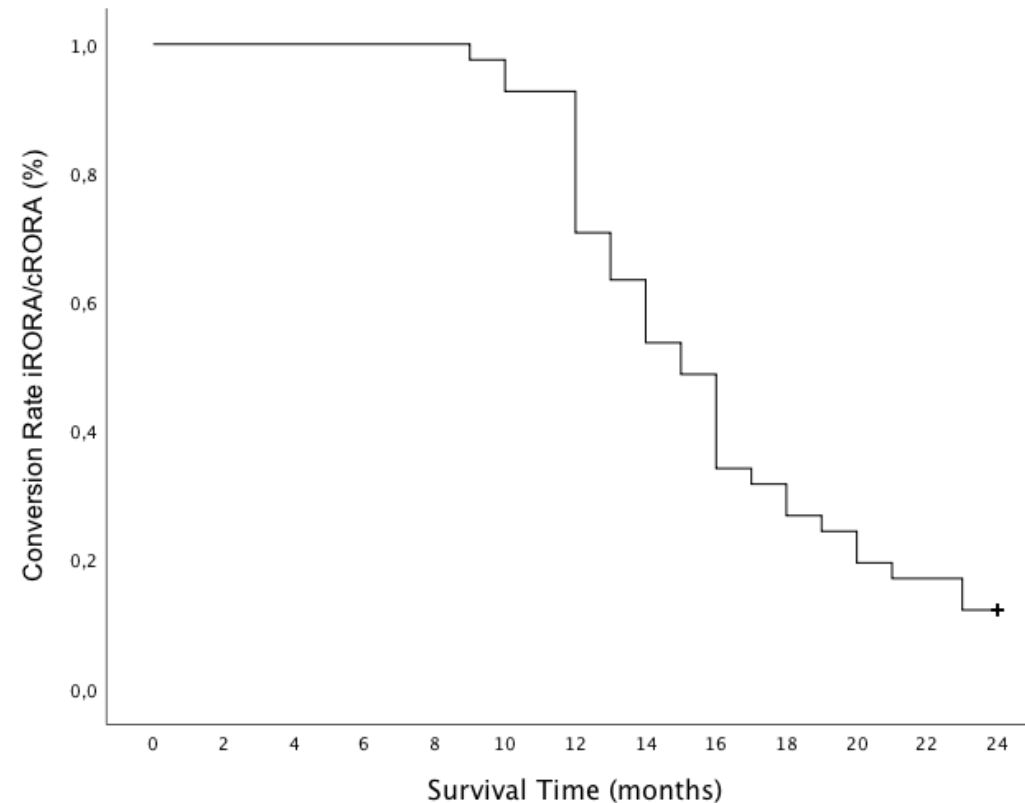
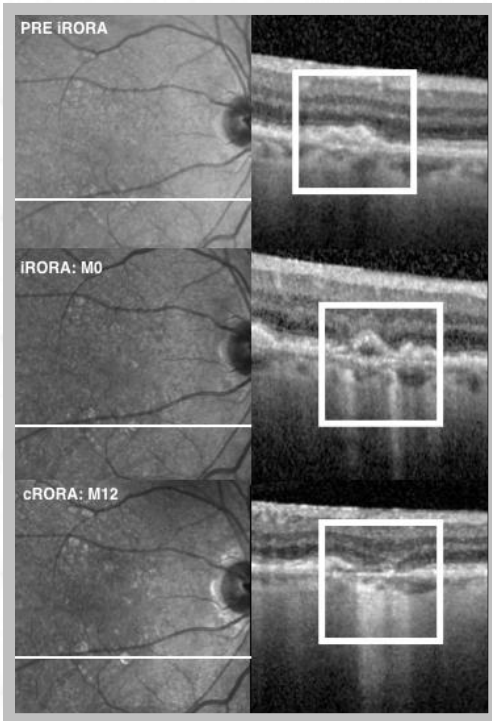
incomplete

RPE and Outer Retinal Atrophy

(nGA is a subset in absence of CNV)

Evaluating AMD progression using new CAM definitions

41 AMD subjects with incident iRORA followed over 24 months



Vast majority of nascent GA lesions progressed to GA over a two-year period

Post-hoc analyses study questions



Can Zimura reduce the progression of iRORA to cRORA over 18 months?



Can Zimura reduce the progression of drusen to iRORA/cRORA over 18 months?

GATHER1 Study methods

Geographic Atrophy Therapy Trial



GATHER1 OCT data transferred to Doheny Image Reading and Research Lab (DIRRL) for masked analysis



Masked readers experienced with grading CAM features



Regions of OCT volume scans more than 500 microns from the border of GA lesion(s) were evaluated at baseline, Month 6, Month 12, and Month 18



Features were assessed in accordance with CAM criteria:

- Progression of iRORA to cRORA
- Progression of drusen to iRORA and/or cRORA

GATHER1

Geographic Atrophy Therapy Trial

Baseline characteristics of study cohort

Number of subjects	Zimura 2 mg* N=58	Sham* N=103
GA lesion size, mean, mm ² (SD)	7.31(3.67)	7.46(3.90)
Presence of large drusen**, n (%)		
n	52	93
Yes	26 (50.0%)	44 (47.3%)
No	26 (50.0%)	49 (52.7%)
Presence of iRORA**, n (%)		
n	52	93
Yes	20 (38.5%)	43 (46.2%)
No	32 (61.5%)	50 (53.8%)
Lesion location:		
Foveal	5 (8.6%)	5 (4.9%)
Extrafoveal	53 (91.4%)	98 (95.1%)
Lesion focality:		
Unifocal	19 (32.8%)	32 (31.1%)
Multifocal	33 (56.9%)	61 (59.2%)
Missing	6 (10.3%)	10 (9.7%)

* Combination of Part 1 and Part 2 subjects.

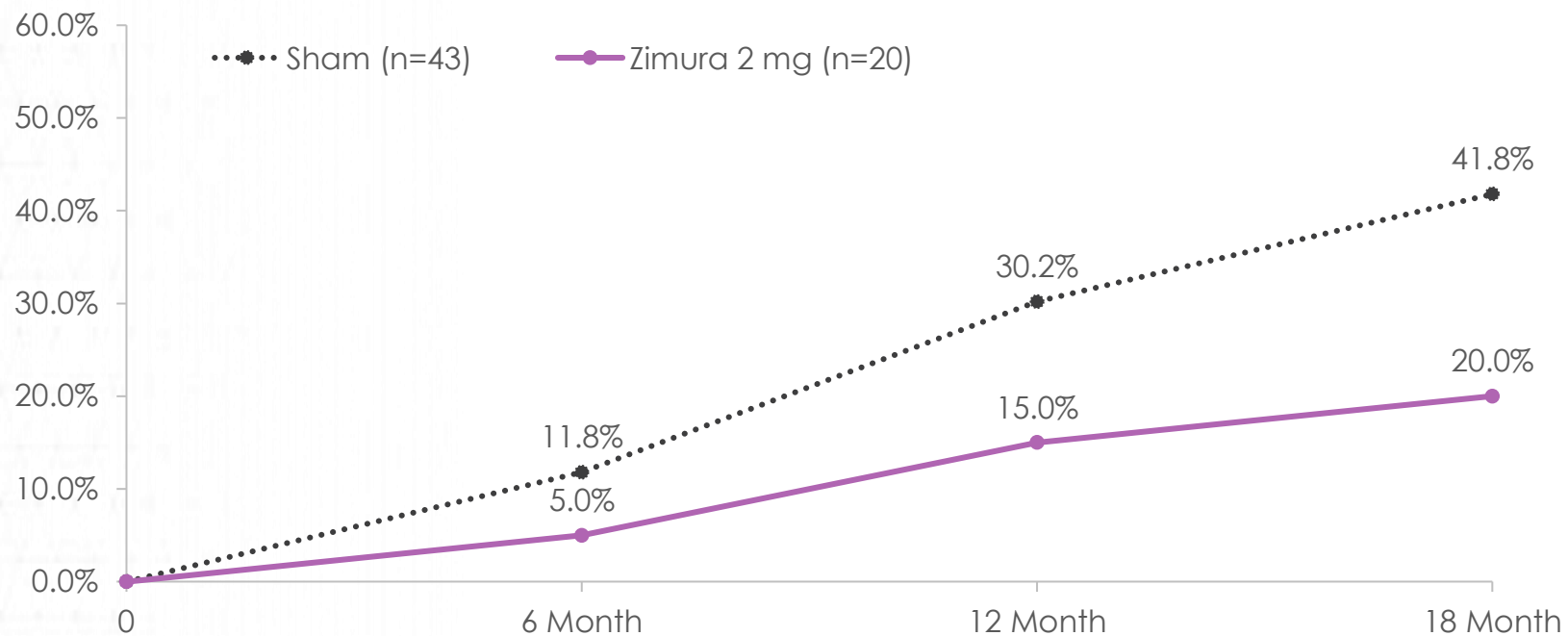
** Percentages are calculated from n.

Full-screen Snip

GATHER 1 Progression of iRORA to cRORA

Geographic Atrophy Therapy Trial

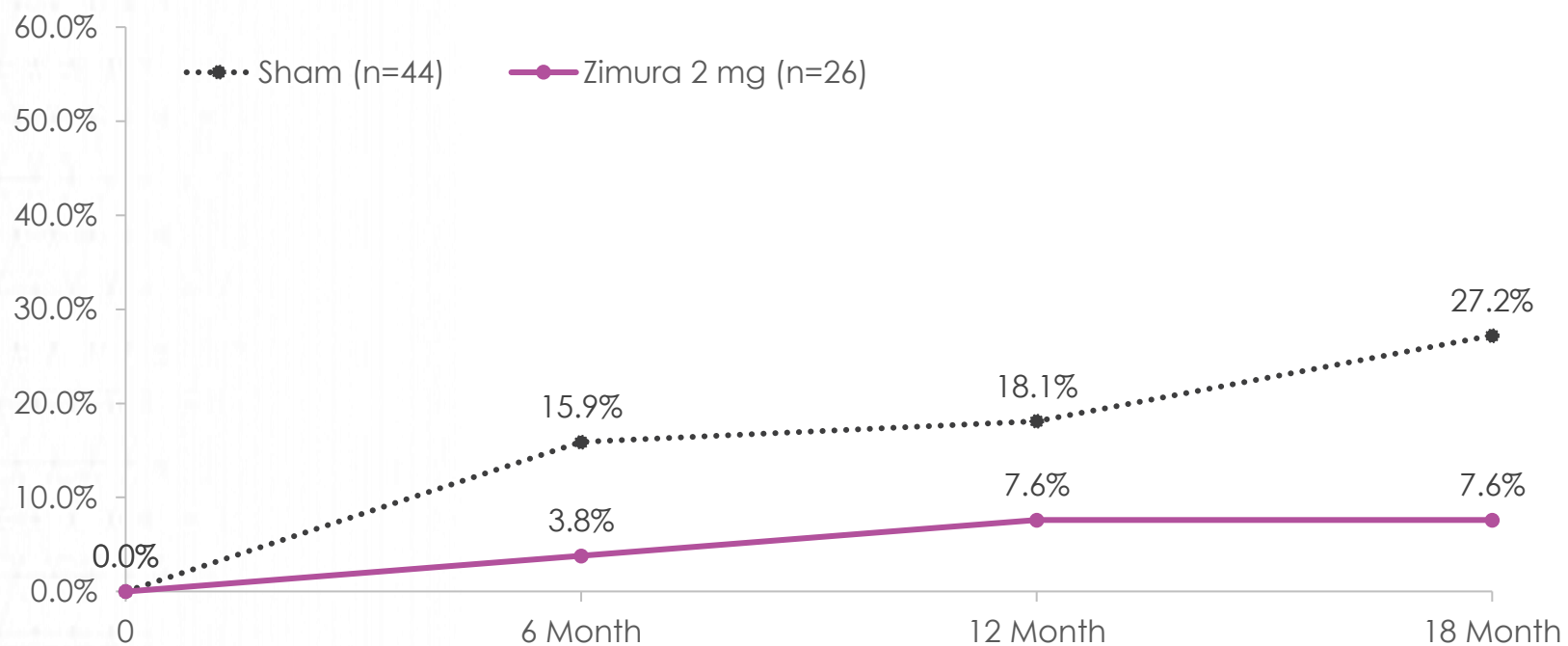
Proportion of patients that progress from iRORA to cRORA (Zimura 2 mg vs. Sham)



GATHER 1 Progression of Drusen to iRORA/cRORA

Geographic Atrophy Therapy Trial

Proportion of patients that progress from drusen to iRORA or cRORA (Zimura 2 mg vs. Sham)



Key takeaways

In this post-hoc analyses of the GATHER1 trial

- ✓ Zimura 2 mg was associated with greater numerical reduction compared to sham in the progression of iRORA to cRORA, and this was evident as early as 6 months, and with an increasing separation between Zimura and Sham over time
- ✓ Zimura 2 mg was also associated with a greater numerical reduction compared to sham in progression of drusen to iRORA or cRORA, with no additional patients developing iRORA or cRORA following Month 12 in the Zimura arm, in contrast to the sham arm
- ✓ As this is a post-hoc analysis, the results should be considered as hypothesis-generating only, but they do suggest that further exploration of Zimura in dry AMD is warranted



EXPANDING BEYOND COMPLEMENT

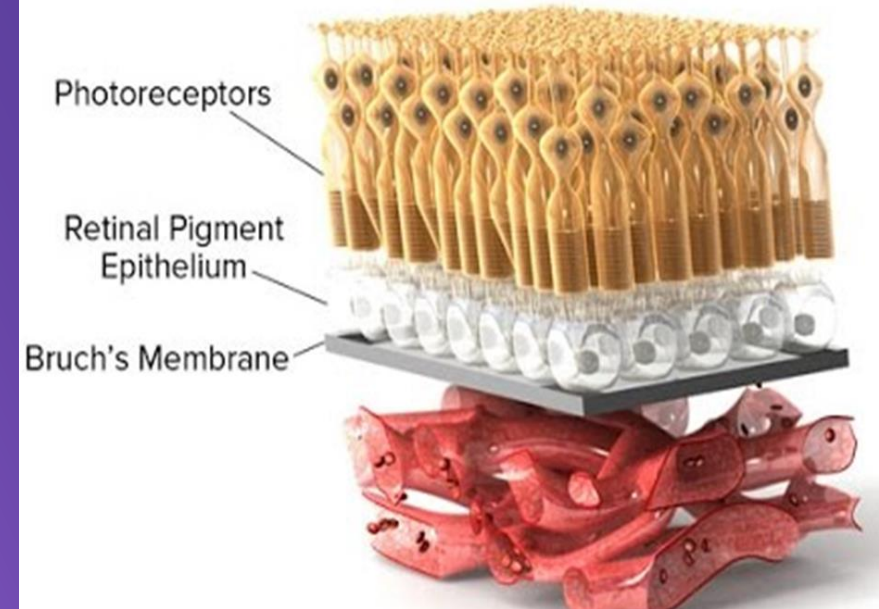
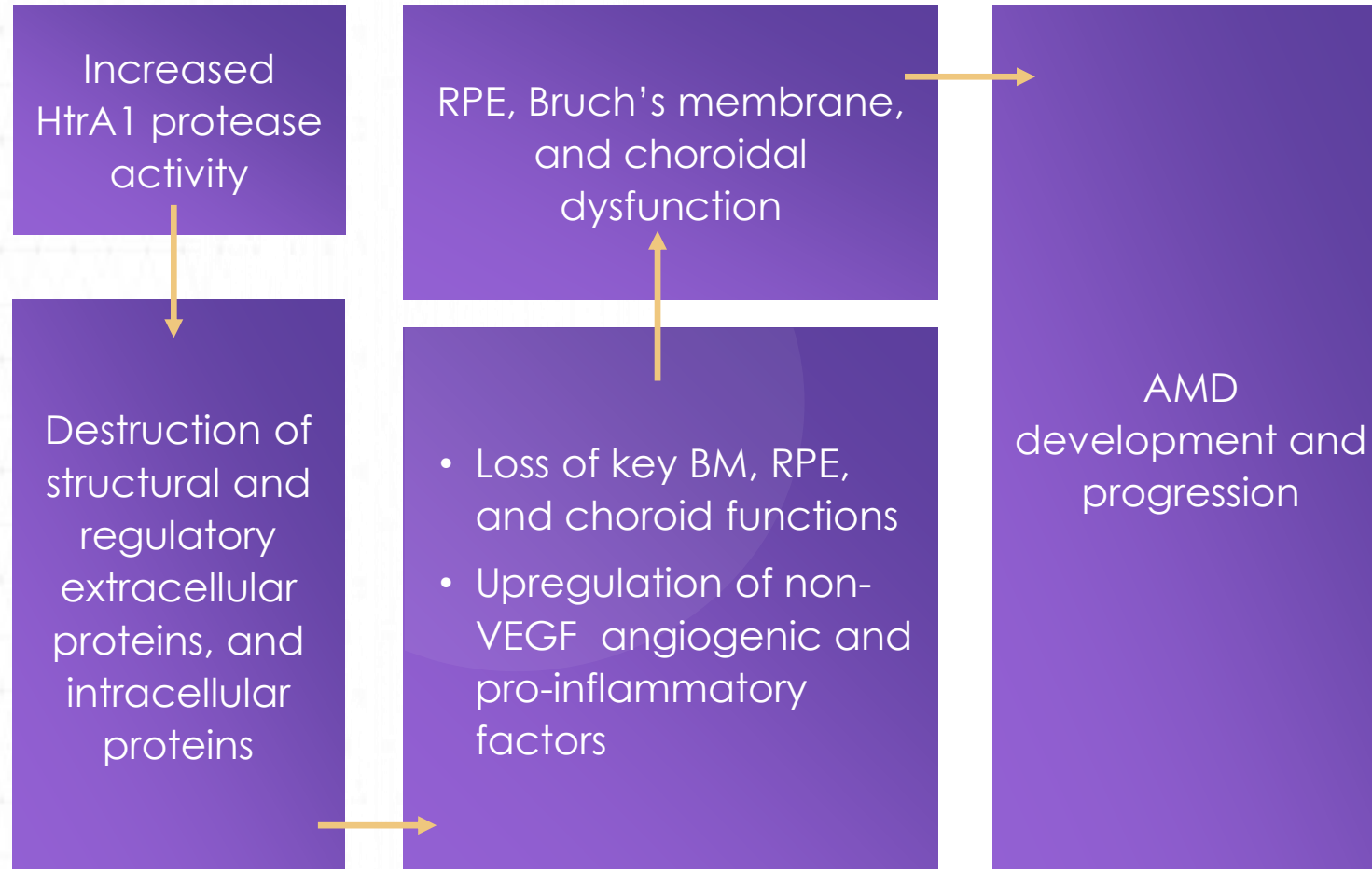
HtrA1 in AMD

PETER KAISER, MD

Chaney Family Endowed Chair for Ophthalmology Research
Professor of Ophthalmology
Cleveland Clinic Lerner College of Medicine

Proposed mechanism of HtrA1 activity in AMD

Destruction of extracellular matrix proteins leads to epithelium dysfunction



Evidence for the role of HtrA1 in AMD pathogenesis

Target backed by strong human genetic and pre-clinical/clinical evidence

- ✓ Strong human genetic evidence associates ocular HtrA1 overexpression with geographic atrophy and all neovascular forms of AMD
- ✓ Compelling preclinical and clinical evidence for role of HtrA1 in AMD
- ✓ HtrA1 is non-overlapping and could augment the effects of targeting other AMD treatment pathways

Intracellular and extracellular HtrA1 activity may be important in the development of AMD



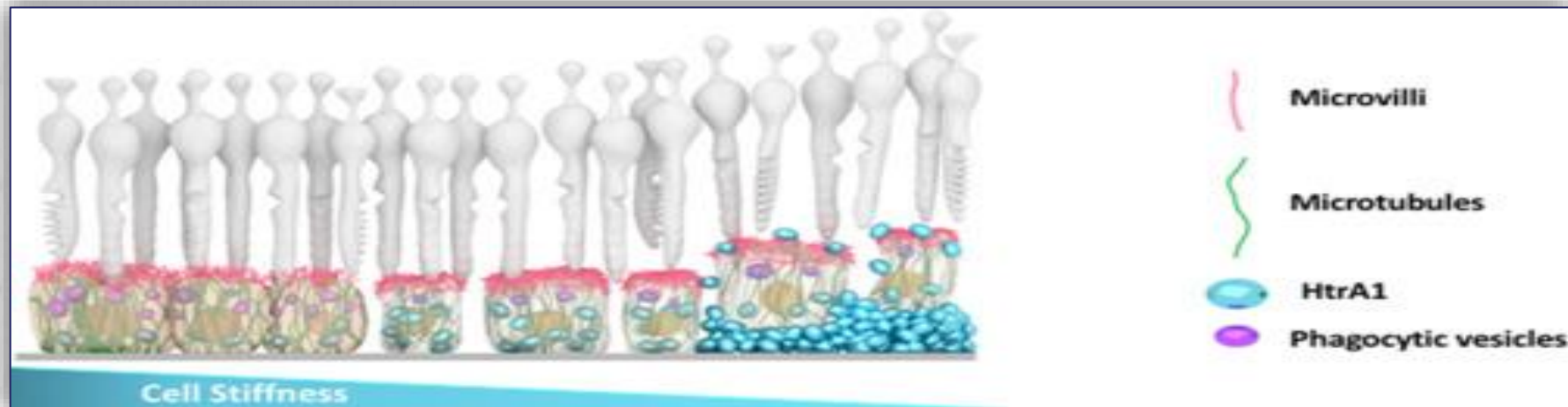HtrA1 protein exists both intracellularly and as a secreted protease



Several intracellular and extracellular targets of HtrA1 proteolysis have been reported



Overexpression of HtrA1 in human primary, polarized RPE demonstrated deleterious intracellular effects



Genentech's RG6147 anti-HtrA1 molecule is in Phase 2 development for GA

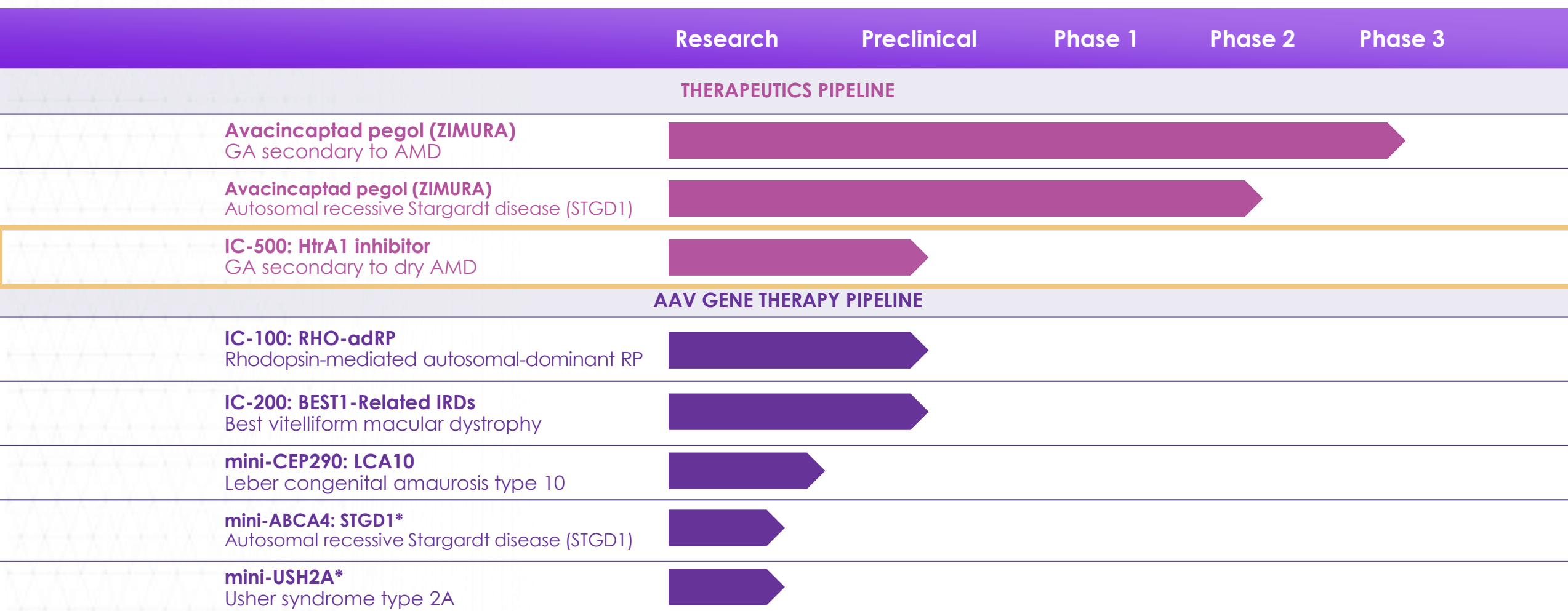
Genentech Moves GA Therapy to Phase 2 Trial

■ Following a successful 15-patient phase 1 safety study of intravitreal anti-high temperature requirement A1 (anti-HtrA1), a novel serine protease inhibitor in patients with GA, Genentech has moved on to the 285-patient GALLEGRO phase 2 study evaluating the therapy's efficacy at 4 and 8 weeks. Anti-HtrA1 is a fab of a humanized monoclonal antibody designed to inhibit HtrA1 activity. HtrA1 is associated with progression of macular degeneration from intermediate to advanced stage and increased lesion growth rates in GA.

The phase 1 safety study evaluated the safety, tolerability, pharmacokinetics and pharmacodynamics (PD) of anti-HtrA1 following single and multiple doses in patients' GA secondary to wet AMD, administered via intravitreal injection. Results were presented by Dante Pieramici, MD, at the 2020 ARVO virtual meeting.

Anti-HtrA1 treatment was well tolerated at single doses up to 20 mg and multiple doses of 20 mg every 4 weeks. No dose-limiting toxicities were observed and no ocular serious adverse events (AEs) or systemic or ocular AEs were reported related to anti-HtrA1. Furthermore, a sustained PD effect suggests a potential for at least 8 weeks of target inhibition.

Iveric Bio's IC-500 program targets HtrA1



Molecular, biochemical, and physical attributes of IC-500

Attribute	IC-500
Molecule Type	Small Molecule
Mechanism of Inhibition	Active Site Binding Intra- and Extracellular HtrA1
Potency (IC ₅₀)	10 nM
Selectivity (HtrA1 vs HtrA2)	580-fold
Formulation	Suspension for IVT
Durability	Up to quarterly dosing may be possible

Key takeaways

- ✓ HtrA1 protein is widely expressed, and found in many tissues of the eye
- ✓ Genetic studies suggest a strong link between HtrA1 and development and progression of AMD
- ✓ HtrA1 is overexpressed in the eyes of patients with AMD
- ✓ Iveric Bio's IC-500 is designed to inhibit both intra- and extracellular HtrA1, further pre-clinical studies are ongoing to confirm this mechanism of action



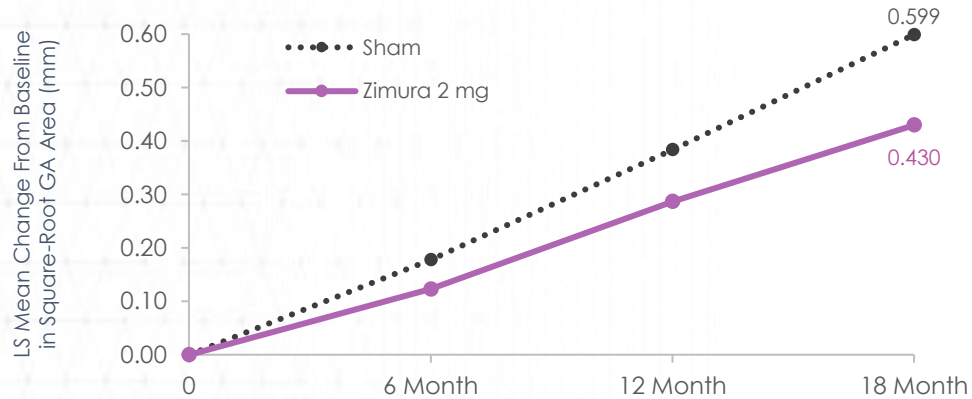
DRY AGE-RELATED MACULAR DEGENERATION

Virtual Symposium for Investors and Analysts

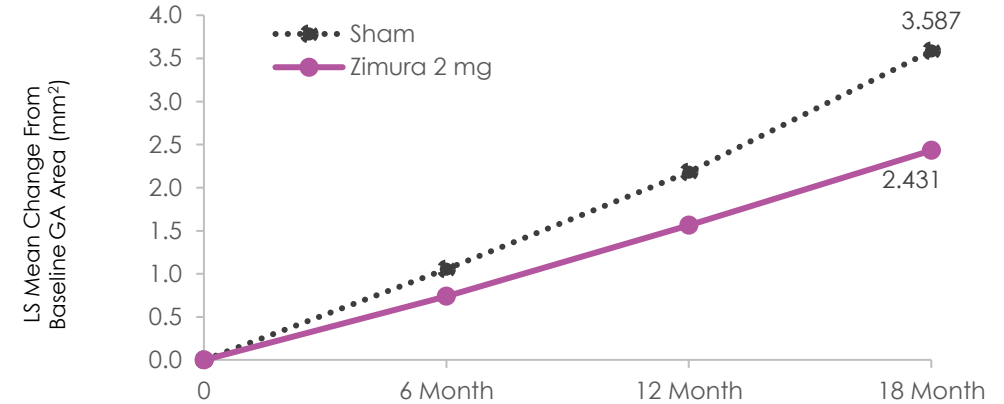
PANEL DISCUSSION

Potential to alter natural history of disease

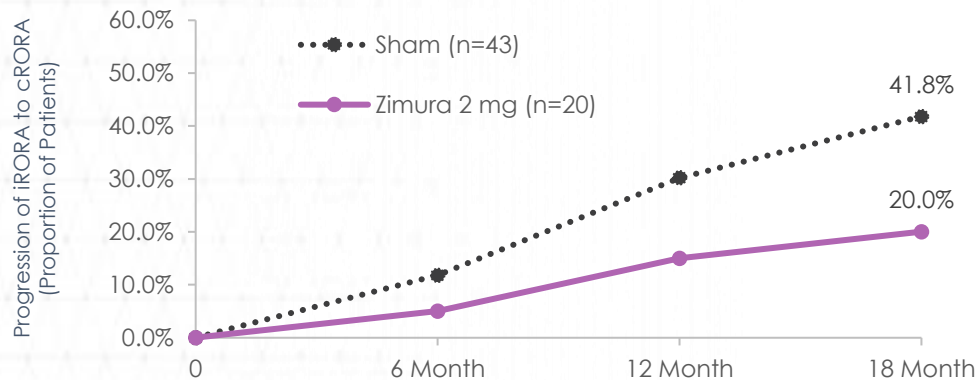
Zimura 2 mg vs sham (square root transformation)



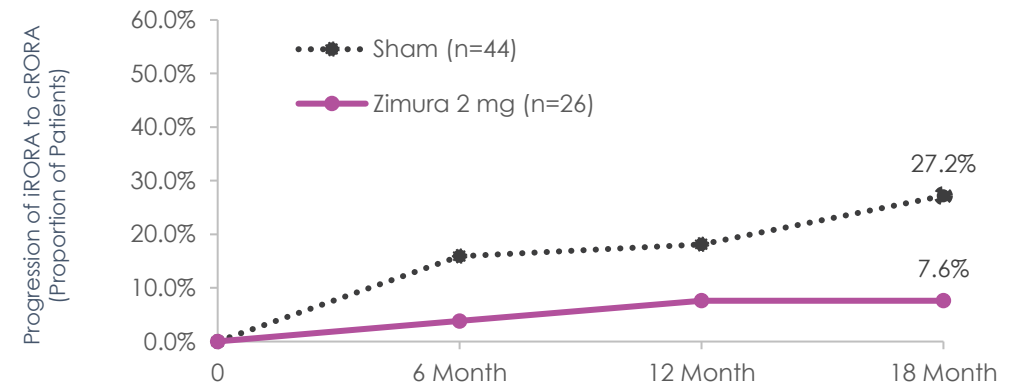
Zimura 2 mg vs sham (non-square root transformation)



Progression of iRORA to cRORA (post-hoc analysis)



Progression of drusen to iRORA/cRORA (post-hoc analysis)





DRY AGE-RELATED MACULAR DEGENERATION

Virtual Symposium for Investors and Analysts



THANK YOU